

1959

Neuroanatomy of the brachial plexus of the dog

John Gilbert Bowne
Iowa State University

Follow this and additional works at: <https://lib.dr.iastate.edu/rtd>

 Part of the [Animal Structures Commons](#), and the [Veterinary Anatomy Commons](#)

Recommended Citation

Bowne, John Gilbert, "Neuroanatomy of the brachial plexus of the dog " (1959). *Retrospective Theses and Dissertations*. 2146.
<https://lib.dr.iastate.edu/rtd/2146>

This Dissertation is brought to you for free and open access by the Iowa State University Capstones, Theses and Dissertations at Iowa State University Digital Repository. It has been accepted for inclusion in Retrospective Theses and Dissertations by an authorized administrator of Iowa State University Digital Repository. For more information, please contact digirep@iastate.edu.

NEUROANATOMY OF THE BRACHIAL PLEXUS OF THE DOG

by

John Gilbert Bowne

A Dissertation Submitted to the
Graduate Faculty in Partial Fulfillment of
The Requirements for the Degree of
DOCTOR OF PHILOSOPHY

Major Subject: Veterinary Anatomy

Approved:

Signature was redacted for privacy.

In Charge of Major Work

Signature was redacted for privacy.

Head of Major Department

Signature was redacted for privacy.

Dean of Graduate College

Iowa State College

Ames, Iowa

1959

TABLE OF CONTENTS

I. INTRODUCTION	1
II. REVIEW OF LITERATURE	3
III. MATERIALS AND METHODS	25
IV. INVESTIGATION AND FINDINGS	44
V. DISCUSSION	157
VI. SUMMARY AND CONCLUSIONS	167
VII. LITERATURE CITED	171
VIII. SELECTED BIBLIOGRAPHY	176
IX. ACKNOWLEDGMENTS	183

I. INTRODUCTION

There is a paucity of literature on "so-called" radial paralysis in the dog. The literature on the gross anatomy of the brachial plexus of the dog is not entirely adequate from the clinical point of view. Literature is incomplete or absent on experimental reproduction of the many syndromes of brachial plexus avulsion. At the present time, the functional evaluation of all the nerves of the brachial plexus of the dog is lacking in the literature.

The instability of the pectoral girdle of the dog and the position of the nerves of the brachial plexus as they course around the first rib may contribute to the ease with which injuries are sustained by the plexus. Automobile accidents that involve the shoulder may displace the shoulder and scapula caudally thus putting a great deal of tension on all the nerves of the brachial plexus. The pressure may be from a cranio-medial direction and severe abduction of the scapula may tear the roots of the brachial plexus from the spinal cord.

Many animals are euthenized or the affected limb amputated because of the present lack of understanding of the brachial plexus paralysis syndrome. Neurosurgery is infrequent in veterinary medicine because of a lack of basic information and techniques.

The etiology of radial nerve paralysis was thought by some observers to be due to trauma to the radial nerve as it courses from a medial to a

cranial position around the musculospiral groove of the humerus. The affection is still called "musculo-spiral paralysis" in some textbooks.

The brachial plexus presents a formidable picture to the small animal surgeon because it is so deeply situated in a maze of large blood vessels. However, the brachial plexus of the dog may be entered without resorting to transection or undue trauma of any of the muscles which seemingly make an unpenetrable obstacle to surgery of the brachial plexus of nerves.

It is the purpose of this investigation to report some of the basic information necessary, from a functional anatomical approach, to facilitate an accurate evaluation of clinical cases of brachial plexus avulsion.

II. REVIEW OF LITERATURE

A. Macroscopic Anatomy of the Brachial Plexus

The experimental embryologist has contributed a great deal to our knowledge of the morphogenesis of the brachial plexus. Therefore, it seems appropriate to include a brief review of this aspect for a better understanding of the formation of the brachial plexus of nerves in the dog. However, this investigation is concerned primarily with the applied anatomical and clinical aspects of the brachial plexus of nerves in the dog, and consequently not all of the literature pertaining to embryological origin of nerve plexuses will be included.

Lehmann (1927) concluded that the mesodermal somites are responsible for the development of spinal ganglia and the location of the sensory and motor roots. Detwiler (1934, 1935) working with *Amblystoma* embryos obtained irregular development of spinal ganglia in the complete absence of somites. He concluded that the crest cells have a certain self-differentiating capacity and can develop independently of developing muscles and cartilage. He agreed with Lehmann in determining that segmentation in the nervous system is dependent upon the mesodermal somites. Miller and Detwiler (1936) demonstrated that the nerves which make up the brachial plexus correspond segmentally to the somites beneath which the embryonic forelimb bud lies.

Barron (1946) states that the neuroblasts that form the lateral column of the spinal cord appear to be derived from two sources: the medullary epithelium and from the mantle layer. The epithelial neuroblasts (primary neuroblasts) begin their differentiation in the epithelial layer and migrate into the mantle layer. The neuroblasts which arise in the mantle layer (secondary neuroblasts) are from indifferent cells. Barron (1943) states that only those indifferent cells differentiate into neuroblasts that are in close association with growing dendrites. He states that it is possible to correlate, in sheep, the arrival of the axons in the anlagen with the appearance of dendrites on the neuroblasts of the associated column in the cord.

Wenger (1951) transplanted different segments of chick spinal cord and substituted them for other segments. He pointed out that either thoracic or cervical cord can give rise to nerves which form a normal brachial plexus pattern. He stated that plexus patterns are imposed upon outgrowing nerves by factors present in the mesoderm.

Willier, Weiss, and Hamburger (1955) state that the pioneering nerve fibers lay down the primary nerve connections to the nerveless tissue of the appendage. They state that nerve fibers cannot penetrate structureless space or liquid, but proceed along interfaces in the developing appendage. Weiss (1941) named the principle according to which nerve fiber tips are guided in their course by contact with surrounding structures as "contact guidance". Hamburger and Keefe (1944)

demonstrated that proliferation and cellular differentiation are independently variable. Differentiation of motor neurons is under the control of non-nervous peripheral structures. They produced hypoplasia of motor neuroblasts by extirpation of a wing bud. However, the total number of cells remained constant for operated and unoperated sides. The difference was in the number of non motor cells that were induced to differentiate into neuroblasts under the influence of the pioneering motor nerves.

The Rolleston-Furginger theory postulates that each motor nerve bears a constant relation to its corresponding myomere throughout both phylogeny and ontogeny. In other words each muscle slip, no matter how distant it may end up from its original position during evolution, will always be innervated by the motor nerve of its original segment. Howell (1933) restated the theory to read: "That the relation of a muscle to its original motor nucleus in the central nervous system remains forever constant". Howell (1933) believes it to be conceivable that a muscle slip now innervated by the fifth cervical nerve in a mammal may have been derived from one segment higher or (less likely) lower in an ancestral form. According to Hines (1927), in mammals and in the frog the same muscle fiber may be supplied by motor twigs from two, or even three adjoining neuromeres.

Ramon y Cajal (1928) states that the actual connection between

nerve and muscle by motor end plates is not effected until a stage at which practically all the muscle divisions have become differentiated. Howell (1933) believes that the most likely explanation of the formation of the limb plexuses lies in the fact that some of the appendicular muscles of relatively small size are derived from a number of myomeres. Therefore, the nerves are closely grouped and parts of them may come to be enclosed in a single sheath forming a cord. During evolution functional needs cause the muscle layers to split and the nerves to separate with them resulting ultimately in a typical plexus formation.

According to Morris (1953) the brachial plexus of the human being is formed by the anterior primary rami of the fifth to eighth cervical nerves and the greater part of that of the first thoracic nerve. He further noted that the plexus is usually joined by small branches from the fourth cervical and the second thoracic nerves. Morris (1953) describes the brachial plexus as being divided into an upper trunk, composed of the anterior primary rami of the fifth and sixth cervical nerves, a middle trunk composed of the seventh cervical nerve, and a lower trunk composed of the eighth cervical and first thoracic nerves. He further states that each of these divisions is further divided into a lateral cord, formed by the anterior divisions of the upper and middle trunk, a medial cord, formed by the anterior division of the lower

trunk, and a posterior cord, composed of the posterior divisions of all the trunks and nerves. Thorek (1951) concurs with the description by Morris.

Kerr (1918) made a very extensive study of the brachial plexuses of a great number of human cadavers. Most of the descriptions found in modern human anatomy textbooks are based on Kerr's original work.

The origin and immediate distribution of the human brachial plexus is entirely different from that of our domestic animals, so that the detailed descriptions of human anatomy cannot be utilized in veterinary anatomical descriptions.

According to Miller (1952) the brachial plexus of the dog originates from the ventral divisions of the sixth, seventh, and eighth cervical spinal nerves, and the first and second thoracic spinal nerves. He states that a small part of the first thoracic and the bulk of thoracic two form the first and second intercostal nerves respectively. Bradley (1948) agrees with Miller's description of the origin of the brachial plexus of the dog. Bradley says the plexus is located between the axillary vessels and scalenus muscles. Sisson and Grossman (1953) state that the brachial plexus of the dog originates from the ventral branches of the last four cervical and first thoracic spinal nerves. Allam, Lee, Nulsen and Fortune (1952) state that 58.62% of the brachial plexuses that they dissected were formed from roots from cervicals six, seven, eight and thoracic one; 20.69% by roots from

cervicals five, six, seven, eight and thoracic one; 17.25% by roots from cervical six, seven, eight and thoracic one and two, and that 0.034% of the brachial plexuses possessed contributions from cervical nerves five through thoracic two.

Yeary (1956) states that the brachial plexus is composed of the last three cervical and first thoracic nerves, however, he innumerates them as cervical five, six and seven. He does not mention cervical eight in any of his discussion. He mentions the middle cord as originating from cervical seven and his results of stimulation are similar to those obtained when the cord formed by the eighth cervical nerve is stimulated.

Clifford, Kitchell, and Knauff (1958) state that the brachial plexus of the dog is formed by the ventral branches of the sixth, seventh, and eighth cervical nerves and the first thoracic nerve.

This investigation concerns the brachial plexus and its immediate distribution in the axilla. Therefore, the review of literature will include the anatomy of the brachial nerves only as far distally as the elbow joint.

According to Miller (1934) real trunk or cord formation cannot be distinguished in the dog. She states that the roots break up into anterior and posterior divisions shortly after they emerge from the intervertebral foramina. The anterior division forms the ulnar and median nerve

trunk and the posterior division forms the radial nerve trunk. She says that the upper two roots furnish very little to the terminal nerves of the plexus. Miller (1934) further states that this type of plexus accompanies shoulder muscles that have undergone various adaptive changes coincidental with the lack of a clavicle. Allam et al. (1952) found it convenient to designate three cords, superior, middle, and inferior. The superior cord is 2.5 cm. in length and is derived from cervical seven. The middle cord originates from cervical eight, is 2 cm. in length, and begins just distally to the anastomosing branches from cervical seven and thoracic one. The inferior cord as described by Allam et al. (1952) originates from thoracic one and is located distad to the anastomosing branch from cervical eight and measures 1.5 cm. in length.

The review of literature for the origin and immediate distribution of the various nerves of the brachial plexus will start with the nerves originating in the anterior aspect of the plexus and continue chronologically in a caudal direction.

Miller (1952) says that the brachiocephalic nerve originates from the ventral branch of the sixth cervical spinal nerve. Bradley and Graham (1948) agree with Miller. Allam et al. (1952) state that when the fifth cervical nerve contributes to the plexus, it anastomoses with the brachiocephalic nerve. Sisson and Grossman (1953) do not discuss the brachiocephalic nerve. Ellenberger and Baum (1943) show the

brachiocephalic nerve originating from the branch of the sixth cervical that combines with a small one from cervical seven to form the suprascapular nerve. Miller (1952) illustrates the suprascapular nerve as originating from the sixth cervical and the seventh cervical spinal nerves. He further shows the subscapular receiving rami from both the sixth and seventh cervical nerves. Allam et al. (1952), Bradley and Grahame (1948) and Ellenberger and Baum (1943) agree with Miller as to the origin and distribution of the suprascapular and subscapular nerves.

Miller (1952) states that the musculocutaneous nerve originates from cervical seven, but has no connection with the eighth cervical nerve. Allam et al. (1952) agree that the musculocutaneous nerve is formed entirely by two filaments from the cranial border of the seventh cervical nerve. Bradley and Grahame (1948) however, show the musculocutaneous nerve receiving a large branch from the seventh cervical and a smaller branch from the caudal border of the eighth cervical trunk. Sisson and Grossman (1953) do not discuss the immediate origin of the musculocutaneous nerve of the dog. Ellenberger and Baum (1943) show the musculocutaneous nerve originating about equally from the sixth and seventh cervical nerves.

Miller (1952) describes the axillary nerve as receiving a large branch from the seventh cervical spinal nerve trunk and a lesser branch

from the eighth cervical nerve. Bradley and Grahame (1948) show the axillary as coming entirely from the seventh cervical. Allam et al. (1952) agree with Bradley and Grahame while Ellenberger and Baum (1943) have the axillary nerve receiving approximately equal contributions from the sixth and seventh cervical nerves.

Miller (1952) states that the radial nerve arises from the last two cervical and first two thoracic spinal nerves. Bradley and Grahame (1948, fig. 2) illustrate the radial nerve as coming mostly from the eighth cervical spinal nerve with an anastomotic branch from the first thoracic. He also shows a branch joining the radial trunk from the axillary nerve trunk. Ellenberger and Baum (1943) describe the radial nerve as originating from the seventh and eighth cervical jointly and receiving a ramus from the first thoracic spinal nerve. Allam et al. (1952) state that the radial nerve trunk is formed from cervical eight with a branch coming from cervical seven and thoracic one. They state that when thoracic two is present it sends a branch to the radial nerve trunk also. Robinette (1955) states that the radial nerve arises from the last two cervical and first two thoracic nerves.

Miller (1952) states that the median-ulnar nerve trunk arises by a common trunk from the eighth cervical and first and second thoracic nerves. Allam et al. (1952) state that the median and ulnar nerves are derived from cervical eight and thoracic one and possibly thoracic two.

Bradley and Grahame (1948) concur with both Miller and Allam et al.

The origins of the superficial pectoral, deep pectoral, lateral thoracic and thoracodorsal nerves will be reviewed as they are important nerves in this investigation. Miller (1952) states that the superficial pectoral nerves leave the seventh and eighth cervical nerves. He states that the deep pectoral derives its supply from the eighth cervical, first thoracic and possibly also the second thoracic spinal nerves, and that the lateral thoracic nerve is a derivation of the deep pectoral. Miller (1952) describes the thoracodorsal nerve as originating mainly from the eighth cervical and by a small branch from the seventh cervical and also the first thoracic spinal nerves. Bradley and Grahame (1948) have the superficial pectoral nerves originating from the musculocutaneous nerve. They have the deep pectoral nerves originating from the eighth cervical and the first thoracic. The thoracodorsal nerve originates from the eighth cervical trunk and the axillary branch of the seventh cervical spinal nerve. They describe the thoracalis longus as originating from the seventh and eighth cervical spinal nerves as they emerge from the intervertebral canal. Bradley and Grahame (1948) do not describe a lateral thoracic nerve. Miller (1952) and Allam et al. (1952) do not describe a thoracalis longus in the dog. However, Ellenberger and Baum (1943) describe the thoracicus longus as originating from the seventh cervical spinal nerve.

They describe a thoracici nerve as originating from the eighth cervical and first thoracic, and from this common stem the ventral thoracic (deep pectoral nerve) and the lateral thoracic nerves originate. They also show the thoracodorsal nerve as originating from the seventh and eighth cervical spinal nerves.

There is general agreement on the course of the rami from the brachial plexus and with muscles that they innervate.

B. Injuries to the Nerves of the Brachial Plexus

1. Clinical picture- etiology and diagnosis

According to Hobday (1953, p. 368) the dog affected with radial nerve paralysis adopts a characteristic attitude:

The elbow is dropped, the wrist flexed and the dorsal aspect of the toes rests on the ground. . . . most cases are due to some severe strain, twist or stretching of the nerve. Injuries to the spine in the region of the first and second thoracic vertebrae may be cited as another cause.

Kirk (1951, pp. 550-551) calls the affection "musculospinal paralysis" or "dropped elbow". "It arises from blows or other injuries in the region of the elbow". Robinette (1955) states that among the etiological factors of radial nerve paralysis one should include trauma, muscular rheumatism, sequels of infectious diseases such as distemper, injury to spinal cord, tumors and abscesses. Robinette (1955, p. 43) describes the symptoms as follows:

When the animal is standing still the shoulder and elbow joints are extended, while the other joints are flexed. The elbow joint is at a somewhat lower level on the paralyzed side than on the sound side. Paralyzed extensor muscles are flaccid to touch and soon become atrophied.

Robinette (1955) states that the most prominent symptom of radial paralysis is inability to carry the limb forward. According to Robinette some weight can be supported but that if much weight is transferred to that leg, the joints will give way, the degree depending upon whether the paralysis is complete or partial. He further states that the amount of atrophy of muscle is not a good indication of the severity of the injury because of extensive nerve overlap. He states that the dog is inclined to favor the affected limb at the slightest disturbance, and in many non-nervous ailments he will carry it off the ground. However, with radial nerve involvement the dog will drag the dorsal surface on the ground.

Brumley (1943) describes the symptoms of radial nerve paralysis as an inability to advance the limb, dragging the toe. He describes the symptoms of brachial paralysis as a limp, lifeless condition of the limb in which the animal is unable to support its weight on the affected limb.

Garbutt (1938) states that with a radial nerve paralysis the dog is unable to extend the leg and keeps it bent with the foot turned back. Hutyra, Marek, and Manninger (1938, pp. 413-414)

The shoulder and elbow joints are extended, the other joints flexed; the elbow joint is at a somewhat lower level on the paralyzed than on the sound side. If the leg is straightened by pressure upon the carpal joint the animal can take weight

upon it but on any change of position the joints resume their state of flexion. On walking the leg is advanced by the muscles which draw the shoulder forward, following the line running directly below or slightly external to the body and with the edge of the hood or the tips of the toes dragging on the ground; but as soon as the weight is transferred to that leg the joints promptly give way.

They further state that the extensor muscles are flaccid to the touch and soon become atrophied. They also state that paralysis of all nerve stems entering into the formation of the brachial plexus is rarely observed. Paralysis results from blows in the axilla, wounds of the shoulder region, fractures, and inflammation of the subscapular connective tissue.

It is obvious that more than one syndrome is being described by the preceding workers. Some say the animal cannot advance its leg, others say it can advance the limb. They may all be correct as each is describing a slightly different affection of the brachial plexus.

2. Experimental picture

Worthman (1957) transected the suprascapular nerve which supplies the supraspinatus and infraspinatus muscles; it produced no visible lameness in the dog. He suggested that action by such muscles as the deep pectoral biceps brachii and the brachiocephalicus compensate for the loss of these extensors of the shoulder. He also transected the axillary nerve in the plexus but it produced no pronounced loss of flexion of the shoulder joint. He pointed out that the action of the long

head of the triceps brachii and latissimus dorsi might compensate for the loss of the flexors of the shoulder. The same author transected the radial nerve high in the plexus. He states that because none of the joints other than the shoulder can be extended, the leg can bear no weight. He transected the radial nerve below its branches to the triceps brachii and did not get the same symptoms. Worthman says that with the latter neuroectomy there is a tendency for the dog to knuckle over onto the dorsal side of the paw when walking; however, after a few days the dog learns that a quick flexion of the elbow will flip the carpus and digits into an extended position with the paw on the ground. Cutaneous desensitization is the only way such a neurectomy could be detected. Worthman cut the musculocutaneous nerve which is motor to the biceps brachii and brachialis muscles, and has a large branch to the median nerve. The neurectomy caused little change in the gait. He states that when the dog is standing there is a slight straightening of the elbow. He says that one must assume that the pronator teres and extensors of the carpus and digits are able to flex the elbow joint. He transected the median and ulnar nerves which supply motor fibers to the flexors of the carpus and digits. It caused little or no alteration of the gait. However, he says that if the branch from the musculocutaneous is cut in addition to the median and ulnar nerve the sensory loss is complete. He states that the only indication of muscular

paralysis is a slight sinking of the carpus and fetlock upon application of weight. He believes that because of the humeral attachment of the paralyzed flexor muscles that there is a passive action to effect flexion of the carpus and digits when the elbow is flexed.

Worthman (1957) does not describe any combination of neurectomies such as musculocutaneous-radial, radial-axillary-musculocutaneous, or other combinations. The symptoms that he describes on single neurectomies do not adequately illustrate the syndrome that earlier workers, previously reviewed, have described.

During the course of the present investigation the author has consulted with the small animal clinicians at Stange Memorial Clinic, Iowa State College on cases of brachial plexus avulsion. Simpson (1957)¹ and Jensen (1957)² have described various attitudes displayed by animals presented for treatment, showing brachial plexus involvement. Especially where the avulsion is not complete, the symptoms will vary over a very wide range.

3. Degenerative picture

Burt (1952) compiled an extensive bibliography on development, growth, and regeneration of the nervous system. No attempt will be

¹Simpson, Hugh D. 1957. Ames, Iowa, personally described to the author his experiences concerning radial paralysis syndrome in the dog.

²Jensen, Elroy. 1957. Ames, Iowa, and the author examined a number of dogs showing brachial plexus avulsion.

made by the author to evaluate completely the extensive literature on degenerative changes in the peripheral nervous system.

Maximow and Bloom (1957) describe two events associated with disruption of the nerve fiber. One is associated with the cyton and is termed retrograde cell degeneration, and the other is associated with the sectioned or crushed nerve fiber and is termed Wallerian degeneration.

Maximow and Bloom (1957) state that the Nissl substance dissolves, the volume of the cell increases (due to increased absorption of water) the cell becomes vacuolated, the nucleus is pushed to one side and the cell is in danger of perishing. Clifford, Kitchell, and Knauff (1958) found evidence of chromatolytic changes in a large number of the large central horn cells of the eighth cervical and first thoracic segments in a dog affected with brachial plexus avulsion. These changes were confined to ventral horn cells on the injured side of the body.

Maximow and Bloom (1957) state that the degree of recovery from retrograde cell degeneration is dependent upon where the nerve fibers are damaged. The closer to the cyton the more apt the cyton is to perish.

During the course of the present investigation, the author performed several postmortem examinations on cases showing radial nerve involvement, and in all instances the spinal nerves were

completely avulsed from the spinal cord. The severity of the symptoms is dependent upon whether they are torn loose from the first thoracic or the sixth cervical segments of the spinal cord.

According to Maximow and Bloom (1957) when a nerve trunk is severed, the peripheral or distal portion soon loses its glossy white aspect, becoming a dull gray. The parts of the severed fibers which are an integral part of the neuron, and therefore trophically dependent upon its cell body, undergo complete degeneration. However, the Schwann sheath is trophically independent of the neuron. Therefore, the Schwann cells undergo proliferation. Maximow and Bloom (1957, p. 220) state:

Very soon after section of a nerve the axons near the injury, and distal to it, swell. Within a few days they become fragmented. From the central ends of cut axons numerous new sprouts appear. Later in the first week the myelin segments become discontinuous, forming large irregular ovoids. Schwann cells proliferate, forming strands along the pathway of degenerating fibers. Connective tissue cells increase in number and may form scar tissue at the site of interruption of the nerve.

During the second week, and continuing for many weeks, the myelin ovoids break up into small globules which are gradually removed by macrophages.

Noback and Reilly (1956) state that the first ten days of degeneration have similar histochemical properties to those of normal myelin. They suggested that this period was one of physical fragmentation of the myelin sheath unaccompanied by histochemical evidence of chemical change. They further state that the period from 10 to 130 days after

transection is a period when the physical fragmentation of the sheath is accompanied by chemical changes in the lipids of the myelin sheath.

Causey and Palmer (1953, p. 190) state that:

In the degeneration of myelinated mammalian nerve the myelin retracts from the node during the early stages of degeneration. The area of naked axon at the node is therefore increased. The retraction first affects the nodes close to the lesion producing the degeneration and spreads in a peripheral direction.

Nageotte (1932) says that the rapidity of Wallerian degeneration varies with different species of animals. He states that the axis cylinder fragments and then the myelin sheath breaks up into globules. Small phagocytes (Maximow's polyblasts) derived from tiny ameboid cells contact the sheaths and soon penetrate them. He feels that the phagocytes are engulfing the droplets of axis cylinder and myelin, and the Schwann cells begin to hypertrophy and multiply. At the close of Wallerian degeneration, Nageotte (1932), states that nothing remains but the empty sheath. He reported that these sheaths are often invaded by the new neurites before the destruction of the old neurite is complete. He further states that Schwann cells proliferate around the proximal stump and invade the surrounding tissue like an infiltrating neoplasm, he calls this growth a Schwannoma.

Swank (1940) experimenting on the rat's sciatic nerve, records that the earliest that he could detect degenerative changes after transection was eight hours. He further states that it takes about twenty-four hours after section of the sciatic nerve before any degenerating myelin sheaths

were stained black by the chlorate-osmic acid method. In forty-eight hours a majority of the degenerating sheaths stained.

Rosenblueth and Dempsey (1939) state that the most obvious change in degenerating nerves is their edematous condition. They state that the nerves are stiff and turgid. They weighed equal lengths of normal and degenerating nerves, and found the weight invariably greater in the degenerating nerve. Up to about the fourth day after section there was about a thirty percent difference. They found that the degenerating nerve is less excitable than the normal intact nerve. The spike potential is equal to the normal up to two days after section of the nerve. They said the spikes decrease thereafter, but may still be recorded after four days of degeneration. Conduction velocity was equal or slightly greater than normal during the first two days after resection. It was found that the fatigability of the degenerating nerve was about the same up to the second day after transection, however, on the third and fourth days after transection the degenerating nerves become progressively more fatigable than the normal. Rosenblueth and Dempsey (1939, p. 29) recorded:

At a time when anatomically the structure of the nerve is violently disrupted, its electrical excitability, spike potential and conduction velocity may be practically normal and its fatigability may be only slightly greater than normal.

The facts suggest that irreversible loss of function is quite sudden. Some factor, physical or chemical, diminishes or increases beyond a critical range and conduction immediately disappears.

Logan, Rossiter, and Barr (1953) found that there was a difference in the nuclear population in a degenerating nerve. They quantitatively determined the number of nuclei at 1.0 to 2.7 cm. and 4.3 to 6.0 cm. from the site of section, at sixteen and ninety days after section. They found that at sixteen days, at the 4.3-6.0 cm. distance, there was no increase in the number of nuclei, but at ninety-six days the increase was greater. The increase in nuclear populations in the distal segment was more at both time intervals than in the proximal segment.

Sunderland and Bradley (1950) found that following denervation there was a forty to fifty percent reduction in the funicular area after fifty-nine days denervation, and a fifty to sixty percent reduction at eighty-nine days. At 140 days the residual funicular cross-sectional area was thirty to forty percent of its original value and continued with little change as far as the 485th day:

They also found that there was a reduction in the endoneurial tube area of approximately forty percent after twenty-nine days denervation, eighty percent at the end of fifty-nine days and more than ninety percent from 135 days onwards. The atrophy is greater where the nerve was composed of tightly packed funiculi with little supporting connective tissue, than where the funiculi were widely separated by a large amount of epineural tissue. They further state that in most cases, denervation is followed by an increase in the amount of epineural tissue. These data

indicate the need for quick repair by resuturing to limit the degree of shrinkage of the endoneurial tubes.

Young (1945) states that the axoplasm and myelin are very viscid liquids under a certain amount of pressure. Severance of the nerve eventually releases the pressure. He believes that it is reasonable to suggest that the primary changes which constitute the degeneration of a nerve fiber are a breaking up under surface tension of the viscous cylinders of axon and myelin into shorter segments and ultimately into spheres. The intact cell body produces the pressure necessary to oppose the formation of droplets and presses the contents against the more rigid tube wall and thus maintains the cylindrical form. This type of a theory could account for the lack of chemical change in the sectioned nerve until after the tenth day. Causey and Palmer (1952) emphasize that axoplasm and myelin are immiscible viscous liquids.

Rosenblueth and Del Pozo (1943) state that Wallerian degeneration follows a centrifugal course, that is, the area near the section degenerated more rapidly than the peripheral region. They further state that larger fibers degenerate more rapidly than smaller axons.

All of the papers reviewed agree that degeneration progresses from the site of the severance to the termination.

Sunderland (1946) demonstrated that rupture of the perineurium does not itself lead to total or even widespread degeneration within the bundle.

The only fibers showing degenerative changes in his experiment were those damaged at the site of rupture. Young (1942) states that when the nerve is crushed completely over a length of four centimeters the time of onset of recovery is later than when it is severed, but the final recovery achieved is better than after severance and suture. Many of the traumatic wounds are compression type wounds and complete severance is not accomplished.

Sanders and Young (1944) found that the final diameter of which any regenerating fiber is potentially capable depends on the caliber of its parent fiber in the central stump. Also the maximum diameter which any fiber actually attains in the peripheral stump depends on the size of the particular Schwann tube into which it penetrates. However, long term denervation is accompanied by shrinkage of peripheral Schwann tubes. Thus it is apparent that this information is of prime importance to the surgeon who will ultimately be called upon to repair the neural defects. The reported information indicates that waiting two weeks would allow ample time for the debris to be removed and the epineurium to become strong enough to hold a small diameter silk suture. It also illustrates the urgency of prompt, accurate alignment of the nerve fascicles if functional regeneration is to be accomplished.

III. MATERIALS AND METHODS

A. Macroscopic Anatomy of the Brachial Plexus

1. Dissection procedures

The brachial plexus of nerves was dissected on fifty-four dogs. Twenty-one of the plexuses dissected were from unembalmed cadavers and thirty-one from embalmed animals. The author dissected twenty-one personally and he checked thirty-one plexuses in the student dissection room. Both right and left plexuses were dissected when possible. A drawing was made of the axillary region with the animal in the dorsal recumbency. This drawing was reproduced on type A Kodabromide photographic paper¹. Both right and left sides were reproduced from the same negative. The nerves were traced out very carefully and dissected away from the large blood vessels. They were then drawn on the photograph of the drawing in as near the normal position as it was possible to ascertain. The animals to be embalmed were anesthetized with pentobarbital sodium and exanguinated via a canula in the right carotid artery. They were then embalmed with a solution of formaldehyde, isopropyl alcohol, glycerine (or corn syrup) phenol and water. Red and blue latex were then injected into the carotid artery and angularis oculi vein respectively. Those used for student dissection were injected with

¹Eastman Kodak Company, Rochester, New York.

red latex only. The data were compiled on the drawing and a short description recorded for each nerve, including its course and anastomosis, distally as far as the elbow joint.

2. Faradic stimulation of the nerves of the brachial plexus

Ten mongrel dogs were used for the faradic stimulation of the various nerves of the brachial plexus. The dogs were deeply anesthetized using pentobarbital sodium. One half of the calculated dose of one grain per five pounds of body weight was given very quickly, the remainder was given to effect until the pedal reflex had just about disappeared. If further anesthetic was necessary during the experiment it was given in the ventral lingual vein. At the termination of the experiment the dogs were sacrificed using a massive dose of pentobarbital sodium.

After the dogs were anesthetized the hair was removed from the entire body using a #5 clipper. Small incisions were made over the tuber sacrale, second and third thoracic spines and the crest of the interparietal bone of the skull. A small hole was drilled through each tuber saerale, second thoracic vertebral spine and crest of the interparietal bone of the skull. Sixteen gauge galvanized wire was threaded through the holes in the bones and secured by twisting. An area surrounding the region where the superficial pectoral and brachiocephalicus muscles cross one another was clipped with a #40 clipper and an incision

approximately six inches long was made between the brachiocephalicus and sternocephalicus muscles. The incision was started two inches posterior to the anterior border of the superficial pectoral muscle and extended anteriorly just lateral to the jugular vein. Complete hemostasis was accomplished by ligating the small veins and arteries as the blunt dissection progressed toward the base of the first rib. The only muscle that was necessary to transect was the cutaneous coli muscle. The proximal and distal communicating branches from the cephalic to the external jugular vein were ligated. The descending branch of the omocervical artery was also ligated.

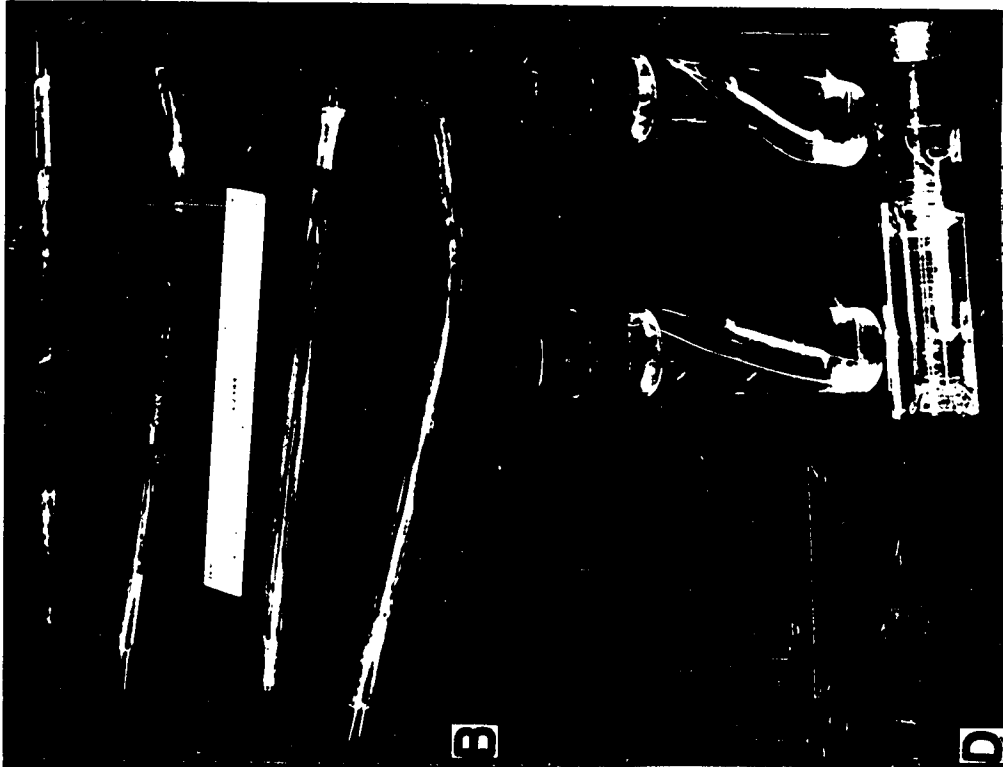
The nerves which were carefully separated from the axillary artery and vein, were ligated proximally and tagged after confirmation using bipolar electrical stimulation.

The dogs were suspended on a pipe frame so that the head, neck and thoracolumbar regions were in the normal position for an animal in the standing position. The volar and plantar surfaces of the paws were just touching the surface of the platform.

The electrical stimulus was furnished by an Electronic Stimulator Model 751¹ (Fig. 1). Just enough electric current was used to elicit a normal response in the muscles. A frequency of 60 cycles per second with a duration of two milliseconds and a strength of 0.4 to 1.5 volts


¹Manufactured by American Electronic Laboratory, Inc. Philadelphia, Pa.

- Fig. 1.
- A. Electronic stimulator used in the investigation.
 - B. Glass and plastic electrodes
 - C. Stainless steel nerve holders used for fixing nerves
 - D. Straight sided rubber corked vials used to fix the nerves and to stain them. Note the nerve holder and nerve lightly stretched between the two ends.



B

D



A

C

was usually used in the faradic experiments. However, the minimum current was determined for each animal.

The electrodes were two wires embedded in bakelite in the shape of a "U". The wires were free in the center of the "U" and a spring loaded clip made of a bakelite block and spring brass was used to hold the nerve in firm contact with the two electrodes.

It was found that the less trauma to the nerve in dissecting it free from the connective tissue in the axilla the better the response to electrical stimulation. It was noted that the ligation affected the metabolism of the nerve eventually and the stimulus had to be increased as the time increased. The ligation was necessary because sensory reflex actions were not desired in the experiment.

The effect of faradic stimulation was recorded on both motion picture film and still black and white and color film. Kodak Tri X negative 16 mm. film¹ was used to record the motion pictures. The speed used was 65 frames per second. This speed slowed the motion down so that it could be accurately described. The still pictures were reproduced on Kodak Panatomic X 35 mm. film¹ using a Leica IIIf camera² equipped with a 90 mm. lens. The motion pictures were illuminated by four 300 watt display type flood lights that were boosted to the right color

¹Manufactured by Eastman Kodak Company, Rochester, New York.

²Manufactured by E. Leitz, Inc., 304 Hudson St., New York 13, N. Y.

temperature using a color transformer. A Heiland Strobnar III Electronic Flash¹ with a duration of one twenty-five thousandth of a second peak was used as a light source for the still pictures. The negative motion picture film was printed on stock film. The edge numbers were developed for accurate identification of frames in future editing. The data were taken from the motion picture film at a speed of 16 frames per second using a standard 16 mm. motion picture projector.

B. Resection of the Nerves of the Brachial Plexus

1. Surgical procedure

Fifty-seven mongrel dogs were used for this portion of the investigation. The dogs were anesthetized with pentobarbital sodium administered intravenously in the cephalic vein. Half of the calculated dose (one grain per five pounds of body weight) was given very quickly and the remainder given to effect until palpebral reflexes were gone, but the pedal reflex was still present. The dog's hair coat was entirely clipped using a #5 clipper. The area over the right axilla, medial aspect of the leg, neck and shoulder was clipped with a #40 clipper. The area surrounding the jugular furrow, superficial pectoral and brachiocephalicus muscles was shaved, defatted with ether, and disinfected with tincture of merthiolate. The dog was secured to the operating

¹Heiland Electronic Company, Denver, Colorado.

table in the dorsal recumbent position. The head and neck were supported in a trough formed by sand bags. The front legs were cross tied under the animal so that an attendant could control the leg that was being operated upon from the opposite side of the table. The front legs were secured with the shoulder joint flexed and the arm and forearm parallel to the thorax. This facilitated free access to the area just anterior to the shoulder joint.

An incision was made just lateral to the thoracic inlet on the right side, extending from a point two inches posterior to the anterior border of the superficial pectoral muscle, to approximately four inches anterior to the pectoral muscle. It extended along the cleft formed by the brachiocephalicus and sternocephalicus muscles. The proximal and distal communicating rami from the cephalic to the external jugular veins were ligated. It was necessary to ligate the descending branch of the omocervical artery on some of the animals. The cutaneous colli muscle was the only muscle that was transected in the approach to the brachial plexus. The plexus and axillary vessels were approached by blunt dissection. The dorsal and ventral bellies of the scalenus muscles were identified and the sixth, seventh, eighth cervical and first thoracic spinal nerves were identified as they pass between the bellies of the scalenus muscle and around the first rib.

The nerves that were to be resected were identified using

faradic stimulation with the Electronic Stimulator and glass and plastic covered sterile electrodes developed specifically for this experiment. The glass and plastic electrode holders were fashioned from three-eighths inch glass tubing. Coated copper wire was soldered to short pieces of #20 nichrome wire. The other end of the copper wire was soldered to one-eighth by one and one-half inch brass welding rod that had been machined to fit into a female plug. Two wires were inserted into a section of glass tubing approximately ten inches long. Selectron 5003¹ plastic mixed with a small amount of Cumene Hydroperoxid² catalyst, was poured into the glass tube and allowed to harden. When the plastic was oven hardened the nichrome wire was cut and the ends polished and bent into a hook so that there was approximately a quarter of an inch between the electrode wires (Fig. 1). The electrodes so embedded in glass and plastic can be sterilized with a 1 : 1000 solution of benzalkonium chloride. A two wire pliable cable was used to connect the electrode holder to the stimulator.

After the nerve or nerves were isolated and accurately identified, a section approximately one inch long was removed. The distal stump was again crushed and identified distal to the crush by faradic stimulation. The proximal stump was crushed to deter any possible

¹Manufactured by Pittsburg Plate Glass Co., Pittsburg, Pa.

²Produced by Hercules Powder Co., Wilmington, Delaware.

regeneration for the duration of the experiment. The accuracy of the neurectomy was again checked at the animal's postmortem examination.

The axilla was allowed to go back against the body wall and the deep layers of fascia were approximated with interrupted #00 chromic surgical gut sutures. The subcutaneous connective tissue was approximated in a similar fashion except a continuous suture was used until the skin edges were in approximation. Vertical mattress sutures of #6N nylon monofilament leader were used to insure the wound edges would not be disrupted due to tension. In every instance the wounds healed by first intention. A surgical dressing was accomplished with gauze pad secured over the wound with flexible collodion. The animals were watched closely as they recovered from the anesthesia to insure a minimum of trauma to the affected leg. The dogs were observed for a period of ten days before motion pictures were taken.

2. Photographic techniques

After the animals recovered from the trauma caused by the surgery they were photographed using similar procedures that have been described previously. The dogs were secured by a short piece of chain, one end of which was attached to their collar and the other end to a ring on a wire stretched eighteen inches above their heads. They were trained to move back and forth in a straight line guided by the wire. This allowed the camera angle to be fairly constant and allowed head on as

well as going away pictures of the lamenesses that appeared with certain neurectomies. Each dog was identified by a number and the name of the neurectomy on a scene board which was then photographed preceding the recording of the lameness.

The still pictures were taken with the same procedure and equipment as described previously.

C. Resection of the Motor Roots to the Brachial Plexus

1. Surgical procedure

A total of fifteen mongrel dogs were used for this phase of the experiment. Three animals were used for each of the following nerves contributing to the brachial plexus: six, seven, and eight cervicals and the first thoracic. Three animals were used in which all of the motor roots, cervical six, seven, and eight and thoracic one, were cut.

The dogs were anesthetized using the same procedure as described previously. An area was clipped over the dorsal and lateral aspect of the thorax and neck. An area from the fourth cervical spine to the third cervical vertebrae was shaved, defatted with ether and disinfected with tincture of merthiolate. The dog was secured to the operating table in a ventral recumbent position with the support of sand bags. The front legs were directed forward and taped together. This separated the dorsal portions of the two scapulae. An incision

approximately six inches long was made just to the left of the midline from the dorsal portion of the third thoracic spinous process to the level of the fourth cervical vertebrae. The trapezius, rhomboideus cervicis, semispinalis capitis (biventer), complexus, spinalis et semispinalis cervicis and multifidus muscles were transected from the first two thoracic and last four cervical vertebrae and the ligamentum nuchae. The muscles mentioned above were isolated and a stump left for eventual suturing. The multifidus and intertransversales muscles were partially removed from the dorsal arches of the last three cervical and first thoracic vertebrae. Using a fascia stripper the fascia and muscles were stripped from the dorsal arches of the vertebrae. A wound retractor developed by Bowne (1958) was used to separate the muscle mass from the ligamentum nuchae and vertebral spines, allowing full visual access to the wounds. Complete hemostasis was accomplished by ligation and sponge pack as the muscles were transected. However, it was found to be very important to stop all seepage before the vertebral canal was opened.

The muscles and fascia were removed laterally as far as the articular processes of the vertebrae. The intervertebral ligament was dissected from the contiguous borders of the vertebrae to be opened. A Ruskin double action rongeur was used to cut the dorsal arches away from the vertebrae concerned. A Kirson laminectomy

punch was used at first, but the space between the spinal cord and the vertebral arch was not enough to use the instrument safely.

The spinal nerves originate segmentally, but only the sixth spinal nerve originates opposite the intervertebral foramen with which it is associated. The sixth spinal nerve roots are also very short which made this motor nerve root the most difficult to remove. The dorsal and ventral roots are separated for only about four millimeters, just about enough to get two hemostats clamped over the ventral motor root. The seventh and eighth cervical spinal nerves originate progressively more anterior to their respective intervertebral foramen. If the entire seventh dorsal arch is removed, both seven and eight ventral motor roots may be transected. The first thoracic spinal nerve originates approximately opposite the eighth cervical vertebrae, however, half of the first thoracic dorsal arch had to be removed to transect the entire motor root. There was a distance of one to one and one half centimeters where the ventral and dorsal roots were not attached on the first thoracic spinal nerve roots.

Hemostats were placed over the motor roots at their origin as they pierced the dural sheath, and another was placed just proximally to the junction of the ventral root with the dorsal root. The section between the hemostats was removed and the hemostats allowed to remain clamped until hemostasis was certain. The defect in the dorsal arches was not

corrected and the muscle sheaths were sutured end to end with #0 chromic surgical gut. The deep fascia was then secured with interrupted sutures. The subcutaneous fascia was secured with continuous suture of #00 chromic surgical gut. The skin was secured with #6N monofilament nylon leader using a vertical mattress suture pattern. The wound was covered with a gauze and flexoseal bandage. Flexoseal was not placed directly over the wound edges. The animals were watched closely as they recovered from anesthesia. The experimental animals were all sacrificed on the tenth day after the nerve resection.

2. Nerves resected and collection procedures

The data collected on the brachial plexus dissections indicated that the fiber contributions to the brachial plexus by cervical five and thoracic two spinal nerves were not great enough to warrant experimentation. There was no way of determining ahead of time whether the plexus received connections from cervical five or thoracic two. Therefore, three animals were used for each of the following ventral motor roots resected: cervical six, seven and eight, and thoracic one. A combination of all four motor roots was resected on each of three different animals. The right brachial plexus on one dog per group served as a control for the experiments.

The sixth motor root of the sixth cervical spinal nerve was cut and the following nerves were collected: brachiocephalic, supra-

scapular, subscapular, musculocutaneous, axillary, sixth cervical spinal nerve, superficial pectoral, coracobrachialis, low median (below anastomosis with musculocutaneous), high radial (its origin in the brachial plexus), low radial (below branches to triceps) and dorsal root of the sixth cervical spinal nerve.

The motor root of the seventh cervical spinal nerve was resected and the following nerves collected: suprascapular, subscapular, musculocutaneous, axillary, high radial, low radial, thoracodorsal, seventh cervical spinal nerve, superficial pectoral, coracobrachialis, low median (below anastomosis with musculocutaneous), brachiocephalicus, dorsal root of seventh cervical, and anastomosis between musculocutaneous and median.

The motor root of the eighth cervical spinal nerve was resected and the following peripheral nerve segments collected: axillary, high radial, low radial, thoracodorsal, median-ulnar trunk, median, ulnar, eighth cervical spinal nerve, lateral thoracic, deep pectoral, coracobrachialis, dorsal root of the eighth cervical, and musculocutaneous nerves.

The motor roots of the first thoracic spinal nerve were resected and the following nerve segments collected: high radial, low radial, median-ulnar trunk, ulnar, median, axillary, thoracic one spinal nerve, lateral thoracic, deep pectoral, thoracodorsal and dorsal root of the

eight cervical spinal nerve.

The motor roots of cervical six, seven and eight and the first thoracic spinal nerves were resected and the following nerve segments collected: brachiocephalic, suprascapular, subscapular, musculocutaneous, superficial pectoral, sixth cervical spinal nerve, sixth cervical dorsal root, coracobrachialis, axillary, high radial; low radial, thoracodorsal, seventh cervical spinal nerve, seventh cervical dorsal root, eighth cervical spinal nerve, eighth cervical dorsal root, median-ulnar trunk, lateral thoracic, median, deep pectoral, ulnar, thoracic one spinal nerve, first thoracic dorsal root, anastomosis between musculocutaneous and median and low median.

After ten days the animals were anesthetized and exanguinated via a canula in the right carotid artery. The pectoral muscles were transected and the rib cage removed allowing free access to the nerves of the brachial plexus. They were very carefully dissected free from the underlying connective tissue. According to Swank and Davenport (1935) trauma to the nerve before fixation will cause traumatic artifacts in the staining of the myelin by the osmic acid. They also stated that undue tension while dissecting the nerve altered the physical form of the myelin so that the nondegenerating myelin stained. In fact they recommended perfusion of the fixative in fixing peripheral nerves. They further stated that ether anesthesia has an effect of increasing the

number of artifacts in the stained nerve.

The author used the utmost care in removal of the nerves so that little tension and trauma were exerted on the nerve trunk. The nerves were isolated for a distance of two inches and a piece of cotton thread tied around each end. The threads were then tied to a loop made out of stainless steel suture wire (Fig. 2). The wire loop allowed just enough tension to keep the nerve taut, but not tight enough to cause tension artifacts. The nerve and wire loop was then placed in a vial of ten per cent neutral formaldehyde for twenty-four hours. The fixing time is critical according to Swank and Davenport (1934a). They found that as the time increased beyond twenty-four hours that the dust type artifacts began to appear. It was necessary to moisten the brachial plexus with saline as the dissection progressed to stop desiccation and staining artifacts.

After the nerves had been fixed for twenty-four hours they were cut into four millimeter lengths and placed in fifteen cubic centimeters of the following solution:

1% aqueous solution of $KClO_3$	60 cc.
1% aqueous solution of osmic acid	20 cc.
Glacial acetic acid	1 cc.
37% (commercial) formaldehyde C. P.	12 cc.

The small pieces of nerves were allowed to remain in the staining solution for ten days. They were then removed and washed in wire baskets for twelve hours, dehydrated in seventy per cent up through

ninety-five percent to absolute ethyl alcohol. The nerves were then placed in a solution of one-half ether and one-half absolute ethyl alcohol for one hour. They were then infiltrated with Altman's paraffin mixture and embedded so that the cross section was exactly perpendicular to the face of the paraffin block. The blocks were then carefully labeled and sectioned at eight to ten microns in thickness.

The serial sections were then affixed to one by three glass slides with an albumin-glycerol solution. Five slides were made from each nerve. One slide was left unstained, deparaffinized and cover slipped. The other slides were stained with Harris' hemotoxylin-eosine, Groats' hemotoxylin and eosin and Mallory's triple stain.

According to Bell, Davidson and Scarborough (1947) normal myelin stains with OsO_4 because the osmic acid is reduced to a black product, probably a lower oxide or metallic osmium, by the reactive unsaturated fatty acids such as oleic acid found in the complex mixtures of fats present in the myelin sheath. If normal myelinated fibers are treated with a mixture of osmic acid and potassium dichromate, the unsaturated fatty acids are quickly oxidized by the dichromate so that they no longer react with the osmic acid. In degenerating nerves, ten days to two months after section, the complex fatty material in myelin breaks down with the formation of large amounts of unsaturated fatty acids which are not entirely oxidized by the dichromate solution.

Therefore; only the degenerating myelin with its excessive unsaturation reduces the osmic acid: According to Swank and Davenport (1934b) $KClO_3$ produces a lighter background and more clearly differentiates the details of the degenerating myelin than the dichromate solution.

IV. INVESTIGATION AND FINDINGS

A. Macroscopic Anatomy of the Brachial Plexus

1. Origin brachial plexus

The brachial plexus of the dog originates from the ventral branches of the fifth, sixth, seventh, eighth cervicals and the first and second thoracic spinal nerves. Table I indicates that in this investigation 3.84 percent of the brachial plexuses originate from cervical five through thoracic two, 55.77 percent, cervical six through thoracic two, 5.77 percent, cervical five through thoracic one and 34.62 percent, cervical six through thoracic one. A great deal of care was taken in dissecting the connections between thoracic two and one. It was found that the anastomatic branch from the second to the first thoracic spinal nerve often passed directly through the stellate ganglion. The second thoracic spinal nerve was listed as a contributor to the brachial plexus if the nerve fibers could be traced through the stellate ganglion to the first thoracic spinal nerve. The connection between thoracic one and two spinal nerves will be resolved definitely only by electro-physiological experimentation or by experimental neural degeneration studies. The author found that the student dissections of the distribution of the fifth cervical nerve were often incomplete and error may be present in the contribution from the fifth cervical spinal

Table 1. Origin of brachial plexus and nerves of the brachial plexus

<u>Brachial plexus</u>						
Origin	C ₅ - T ₂	C ₆ - T ₂	C ₅ - T ₁	C ₆ - T ₁		χ^2
Number	2	29	3	18		35.46 ^a
% Total	3.84	55.77	5.77	34.62		
<u>Brachiocephalicus nerve</u>						
Origin	C ₅ - C ₆	C ₆	C ₆ - C ₇	C ₅ , C ₆ & C ₇		χ^2
Number	4	45	2	1		100.54 ^b
% Total	7.69	86.54	3.85	1.92		
<u>Suprascapular nerve</u>						
Origin	C ₅ - C ₆		C ₆	C ₆ - C ₇		χ^2
Number	1		1	50		88.64 ^c
% Total	1.96		1.96	96.16		
<u>Subscapular nerve</u>						
Origin	C ₆ - C ₇	C ₇	C ₆ & Ax. ^d	C ₆ , C ₇ & Ax.	Axillary	χ^2
Number	35	9	6	1	1	72.72 ^c
% Total	67.31	17.31	11.54	1.92	1.92	

^aP < .005; 3d. f.

^bP < .005; 2d. f.

^cP < .005; 4d. f.

^dAxillary nerve

nerve. Figs. 2, 3, 4 and 5 illustrate the variations in the origin of the brachial plexus of the dog. Figs. 2 and 4 illustrate that when the fifth cervical nerve contributes to the plexus it anastomoses with a branch from the sixth cervical to form the brachiocephalicus nerve. Figs. 2 and 3 illustrate that when the second thoracic contributes to the plexus, it connects with the first thoracic before the branch from the eighth cervical joins to form the median-ulnar trunk. The size of the branches contributed by the fifth cervical and second thoracic spinal nerves are very insignificant when compared with the rest of the spinal nerves contributing to the brachial plexus. Fig. 5 illustrates the most important origin contribution from a functional and clinical point of view. The contribution of the second thoracic spinal nerve to the brachial plexus is hidden to casual observation, and requires radical dissection procedures before it can be isolated. It is never visible when the axilla is opened, and is therefore, of minor importance in surgical evaluation of avulsion of the brachial plexus.

2. Sixth cervical spinal nerve

The sixth cervical spinal nerve usually supplies the brachiocephalicus, suprascapular and subscapular nerves, and sends a branch which anastomoses with the musculocutaneous nerve.

The sixth cervical spinal nerve usually furnishes the entire supply to the brachiocephalicus nerve. When the fifth cervical spinal nerve

Fig. 2. Dissection of the brachial plexus illustrating the origin from the fifth cervical through the second thoracic spinal nerves.

1. Brachiocephalicus
2. Suprascapular
3. Superficial pectoral
4. Subscapular
5. Musculocutaneous
6. Coracobrachialis
7. Axillary
8. Radial
9. Median-ulnar trunk
10. Thoracodorsal
11. Deep pectoral-lateral thoracic trunk

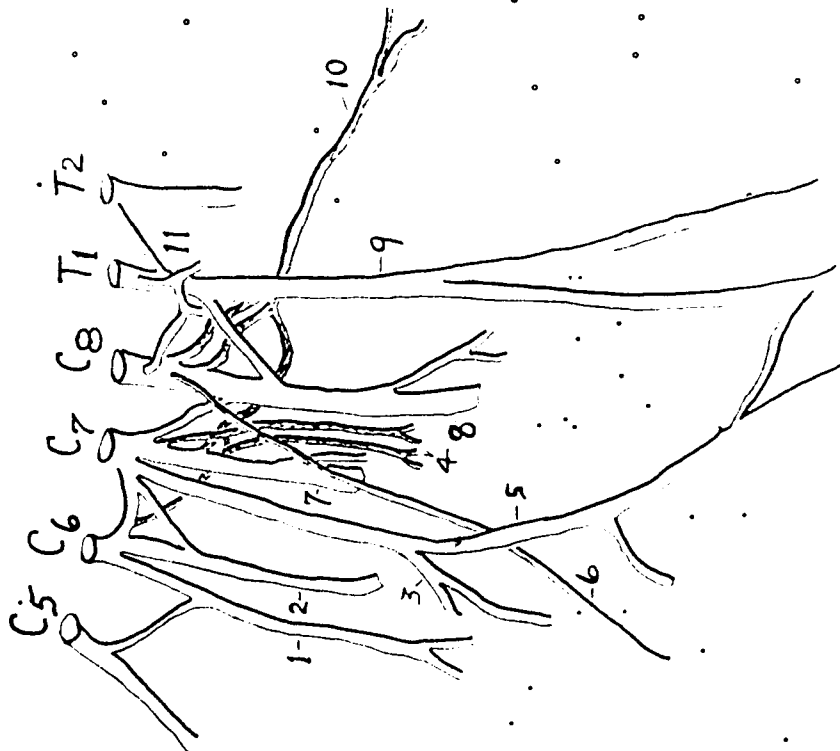


Fig. 3. Dissection of the brachial plexus illustrating the origin of the plexus from the sixth cervical through the second thoracic spinal nerves.

1. Brachiocephalicus
2. Suprascapular
3. Superficial pectoral
4. Subscapular
5. Musculocutaneous
6. Coracobrachialis
7. Axillary
8. Radial
9. Median-ulnar trunk
10. Thoracodorsal
11. Deep pectoral
12. Lateral thoracic

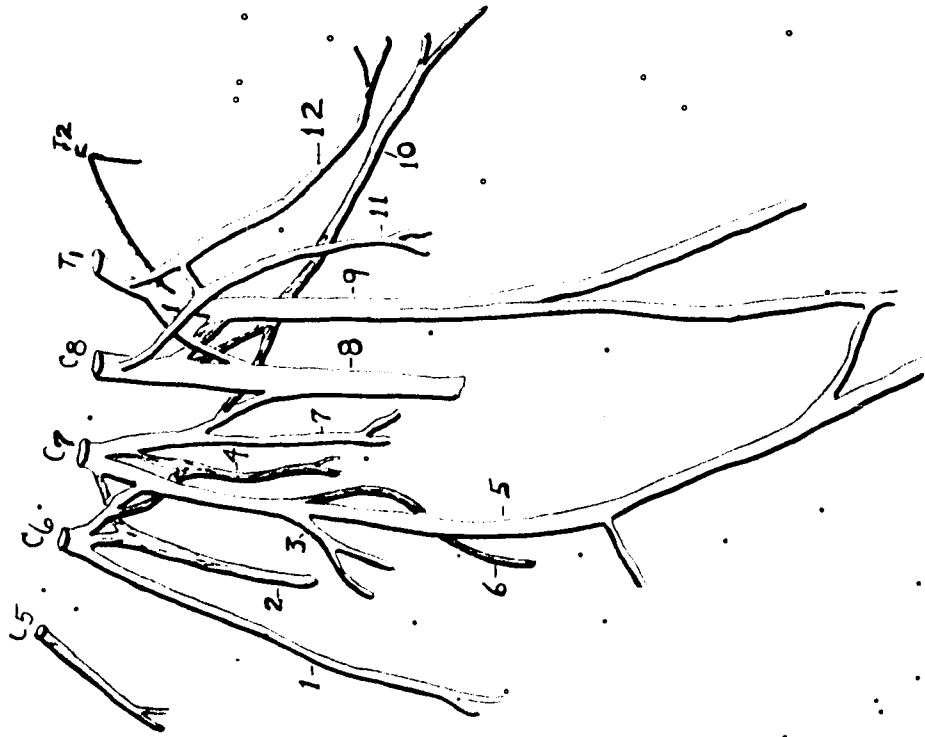


Fig. 4. Dissection of the brachial plexus illustrating the origin of the brachial plexus from the fifth cervical through the first thoracic spinal nerves.

1. Brachiocephalicus
2. Suprascapular
3. Superficial pectoral

Note its origin from the deep pectoral-lateral thoracic trunk and from the eighth cervical spinal nerve.

4. Subscapular
5. Musculocutaneous
6. Coracobrachialis
7. Axillary
8. Radial
9. Median-ulnar trunk
10. Thoracodorsal
11. Deep pectoral
12. Lateral thoracic
13. Deep pectoral-lateral thoracic trunk

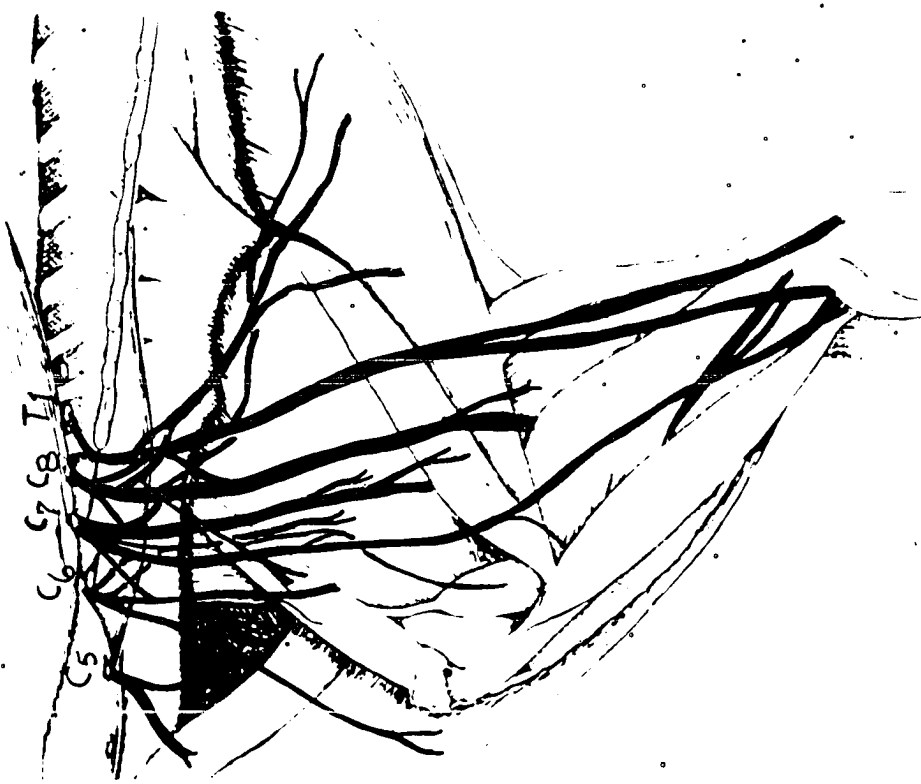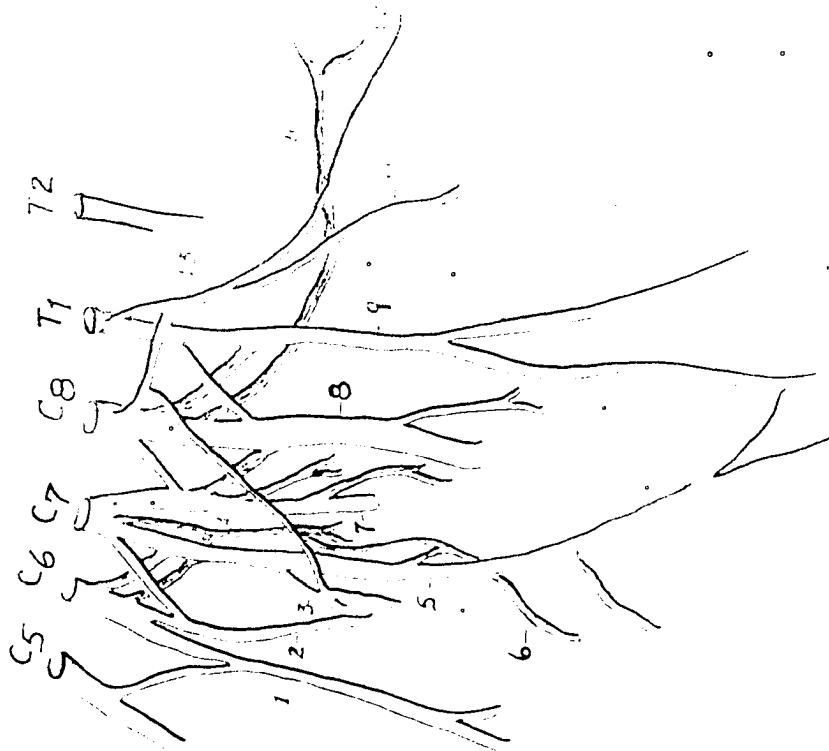



Fig. 5. Drawing of a dissection of the brachial plexus, lateral approach. Illustrating the origin from the sixth cervical through the first thoracic spinal nerves. Note the extent of the dorsal and ventral roots of each of the spinal nerves to the brachial plexus.

1. Sixth cervical spinal nerve
2. Seventh cervical spinal nerve
3. Eighth cervical spinal nerve
4. First thoracic spinal nerve
5. Suprascapular
6. Subscapular
7. Musculocutaneous
8. Radial
9. Axillary
10. Median-ulnar trunk
11. Thoracodorsal
12. Axillary artery
13. Superficial pectoral nerve



contributes to the plexus it supplies the brachiocephalicus. According to Table I, the fifth and sixth cervical form the brachiocephalicus nerve 7.69 percent of the time, however, the most important origin of the brachiocephalicus is from the sixth cervical spinal nerve alone which supplies it in 86.54 percent of the dissections. Table I indicates two additional origins of less importance.

The sixth cervical spinal nerve also forms the suprascapular nerve in 1.96 percent of the dissections, and cervical five and six together in 1.96 percent of the dissections. The most important origin of the suprascapular, however, is via the sixth and seventh cervical spinal nerves (96.16 percent).

The subscapular nerve originates primarily from cervical six and seven (67.31 percent). The subscapular may originate from cervical seven alone or in combination with the sixth and seventh cervical and axillary nerves. Figs. 2, 3, 4 and 5 show only the contributions from the sixth and seventh cervical nerves.

3. Seventh cervical spinal nerve

The seventh cervical spinal nerve usually furnishes most of the innervation to the musculocutaneous, axillary, coracobrachialis, superficial pectoral and sends a large branch to help form the radial nerve.

The musculocutaneous nerve originates 42.31 percent of the time

from cervical six and seven, and 46.15 percent of the time from the seventh cervical spinal nerve only. Table 2 indicates two lesser origins for the musculocutaneous nerve.

The superficial pectoral nerve has four possible origins. The musculocutaneous nerve gives off the superficial pectoral nerve in 45.24 percent of the dissections. Figs. 2 and 3 illustrate this origin of the superficial pectoral nerve. The superficial pectoral nerve also originated from the seventh and eighth cervical spinal nerves in 35.72 percent of the dissections. Fig. 4 illustrates the manner in which the superficial pectoral nerve originates in the latter instance. There are two lesser origin combinations recorded in Table 2.

The coracobrachialis nerve originates 54.17 percent of the time from the musculocutaneous nerve, and 35.42 percent from the musculocutaneous and the eighth cervical spinal nerve. Fig. 3 illustrates the musculocutaneous nerve origin of the coracobrachialis nerve. Fig. 4 shows the coracobrachialis nerve as it originates from the musculocutaneous and eighth cervical spinal nerve. Table 2 records the coracobrachialis originating from cervical eight (Fig. 2) and a lesser combination from the musculocutaneous and the first thoracic spinal nerve.

The axillary nerve originates from the seventh and eighth cervical spinal nerves 50.98 percent of the time and from the seventh cervical spinal nerve alone 47.06 percent of the time. Fig. 4 illustrates the

Table 2. Origin of the nerves of the brachial plexus of the dog

<u>Musculocutaneous nerve</u>					
Origin	C ₆ & C ₇	C ₇	C ₇ & C ₈	C ₆ , C ₇ & C ₈	χ^2
Number	22	24	5	1	28.54 ^a
% Total	42.31	46.15	9.62	1.92	
<u>Superficial pectoral nerve</u>					
Origin	C ₇	Musc. ^b	C ₆ & C ₇	C ₇ & C ₈	χ^2
Number	4	19	4	15	14.48 ^a
% Total	9.52	45.24	9.52	35.72	
<u>Coracobrachialis nerve</u>					
Origin	Musc.	C ₈	Musc. & C ₈	Musc. & T ₁	χ^2
Number	26	4	17	1	30.79 ^a
% Total	54.17	8.33	35.42	2.08	
<u>Axillary nerve</u>					
Origin	C ₆ & C ₇	C ₇	C ₇ & C ₈	χ^2	
Number	1	24	26	20.87 ^c	
% Total	1.96	47.06	50.98		

^aP << .005; 3d. f.

^bMusculocutaneous nerve

^cP << .005; 2d. f.

contribution of the eighth cervical spinal nerve to the axillary nerve. Figs. 2 and 3 show the origin from only the seventh cervical spinal nerve.

4. Eighth cervical spinal nerve

The eighth cervical spinal nerve gives origin to the radial nerve, the thoracodorsal (in part), a large anastomotic branch to the median-
ulnar trunk, the lateral thoracic-deep pectoral trunk (in part) and the coracobrachialis nerve (in part).

The radial nerve is the largest nerve in the brachial plexus. It originated from the axillary, eighth cervical and the first thoracic in 55.77 percent of the dissections, and from the seventh and eighth cervical and first thoracic spinal nerves in 42.31 percent of the dissections. A minor origin is also shown in Table 3.

The thoracodorsal nerve originated from the axillary nerve and the eighth cervical spinal nerve in 34.62 percent of the dissections (Fig. 2). It originated from the anastomotic branch between the seventh and eighth cervical spinal nerves and the eighth cervical spinal nerve in 25.00 percent of the dissections (Fig. 3). It arose from the eighth cervical spinal nerve alone in 21.15 percent of the dissections (Fig. 4). Table 3 indicates four other less important origins for the thoracodorsal nerve.

Table 3. Origin of the nerves of the brachial plexus of the dog

<u>Radial nerve</u>				
Origin	C ₇ , C ₈ & T ₁	Ax., C ₈ & T ₁	C ₈ & T ₁	χ^2
Number	22	29	1	22.66 ^a
% Total	42.31	55.77	1.92	
<u>Thoracodorsal nerve</u>				
Origin	Ax. & C ₈	Ax. & Rad. ^b	Anast. C ₇ -C ₈ & C ₈ ^c	C ₈ & T ₁ · χ^2
Number	18	3	13	5
% Total	34.62	5.77	25.00	9.62
Origin	C ₈	Ax., C ₈ & T ₁	C ₇ & C ₈	
Number	11	1	1	37.72 ^d
% Total	21.15	1.92	1.92	
<u>Median-ulnar nerve trunk</u>				
Origin	C ₈ & T ₁	C ₈ , T ₁ & T ₂	T ₁	χ^2
Number	20	31	1	24.74 ^a
% Total	38.46	59.62	1.92	

^aP < .005; 2d. f.

^bRadial nerve

^cAnastomosis between the axillary and radial nerves; eighth cervical

^dP < .005; 6d. f.

5. First thoracic spinal nerve

The first thoracic spinal nerve gives origin to the median-ulnar nerve trunk, contributes equally with the eighth cervical spinal nerve in the origin of the lateral thoracic-deep pectoral trunk. It also furnishes a large branch to the radial nerve trunk.

The median-ulnar trunk originated from the eighth cervical and first and second thoracic spinal nerves in 59.62 percent of the dissections. In 38.46 percent of the dissections the median-ulnar trunk originated from the eighth cervical and the first thoracic spinal nerves. This variation was due entirely to the contribution of the second thoracic spinal nerve to the brachial plexus. Table 3 shows one other less important origin of the median-ulnar nerve trunk.

The deep pectoral-lateral thoracic trunk has six possible combinations of origin (Table 4). The most important origin is from the eighth cervical and first thoracic spinal nerves. When the second thoracic spinal nerve contributes to the brachial plexus it is assumed that it sends fibers into the deep pectoral lateral thoracic nerve when the latter originates below the junction of the first and second thoracic spinal nerves. This information cannot be obtained by gross dissection procedures.

Table 4. Origin of the nerves of the brachial plexus of the dog

<u>Deep pectoral and lateral thoracic trunk</u>					
Origin	C ₈ & T ₁	C ₈ , T ₁ & T ₂	T ₂	C ₇ & C ₈	χ^2
Number	16	27	2	2	
% Total	32.00	54.00	4.00	4.00	
Origin	C ₈	C ₇ , C ₈ & T ₁			
Number	2	1			53.98 ^a
% Total	4.00	2.00			

^aP << .005; 5d.f.

B. Effects of Faradic Stimulation of the Various Nerves of the Brachial Plexus

1. Brachiocephalicus nerve

Stimulation causes the foreleg to be drawn forward and toward the midline. There is no effect on any joint, the entire limb pivots on the thorax. The effects of brachiocephalicus nerve stimulation is contraction of the brachiocephalicus muscle (in part). The brachiocephalicus muscle will advance the limb if the head is held rigid. See Figs. 7C, 8C and 9D.

2. Suprascapular nerve

Stimulation caused extreme extension of the shoulder joint.

Extension of the shoulder joint invariably occurred no matter whether the shoulder joint was already fully extended or fully flexed. The suprascapular nerve furnishes motor innervation to the supraspinatus and infraspinatus muscles. These muscles supposedly are capable of both flexion and extension, depending on the position of the shoulder joint. See Fig. 9A.

3. Superficial pectoral nerve

Stimulation caused the humerus to be drawn slightly forward and the right foreleg to be adducted until it completely crossed over the left limb. The superficial pectoral nerve supplies the muscles of the same name, which upon contraction cause adduction of the limb. See Figs. 6B, 7B and 9B.

4. Subscapular nerve

Stimulation caused a slight rotation of the foreleg inward and caused the limb to be adducted. The effect of faradic stimulation was not distinct enough to be recorded with still pictures.

5. Musculocutaneous nerve

Stimulation caused flexion of the elbow and flexion of the carpal joints. The shoulder joint was held in a slightly more flexed position.

Fig. 6. Effects of faradic stimulation of the various nerves of the brachial plexus.

- A. Normal prestimulatory pose
- B. Superficial pectoral
- C. Musculocutaneous
- D. Superior radial trunk
- E. Inferior radial trunk
- F. Thoracodorsal
- G. Deep pectoral-lateral thoracic trunk
- H. Median-ulnar trunk

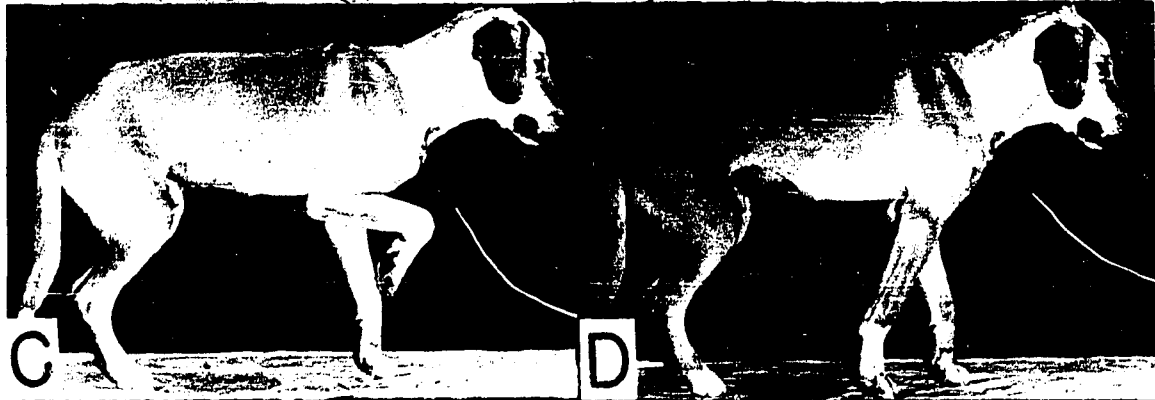

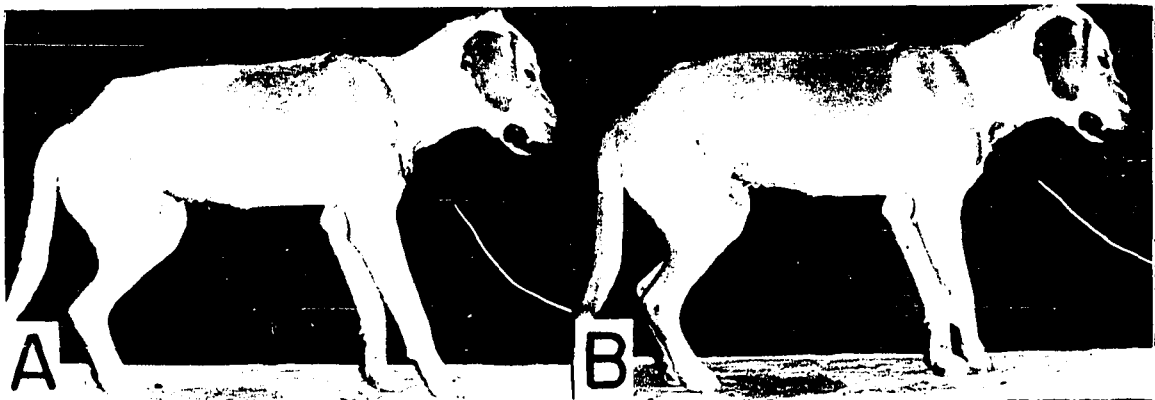


Fig. 7. Close up of foreleg showing the effects of faradič stimulation of the various nerves of the brachial plexus.

- A. Normal prestimulatory pose
- B. Superficial pectoral
- C. Brachiocephalicus
- D. Musculocutaneous
- E. Thoracodorsal
- F. Median-ulnar trunk
- G. Deep pectoral-lateral thoracic trunk
- H. Superior radial trunk
- I. Inferior radial trunk

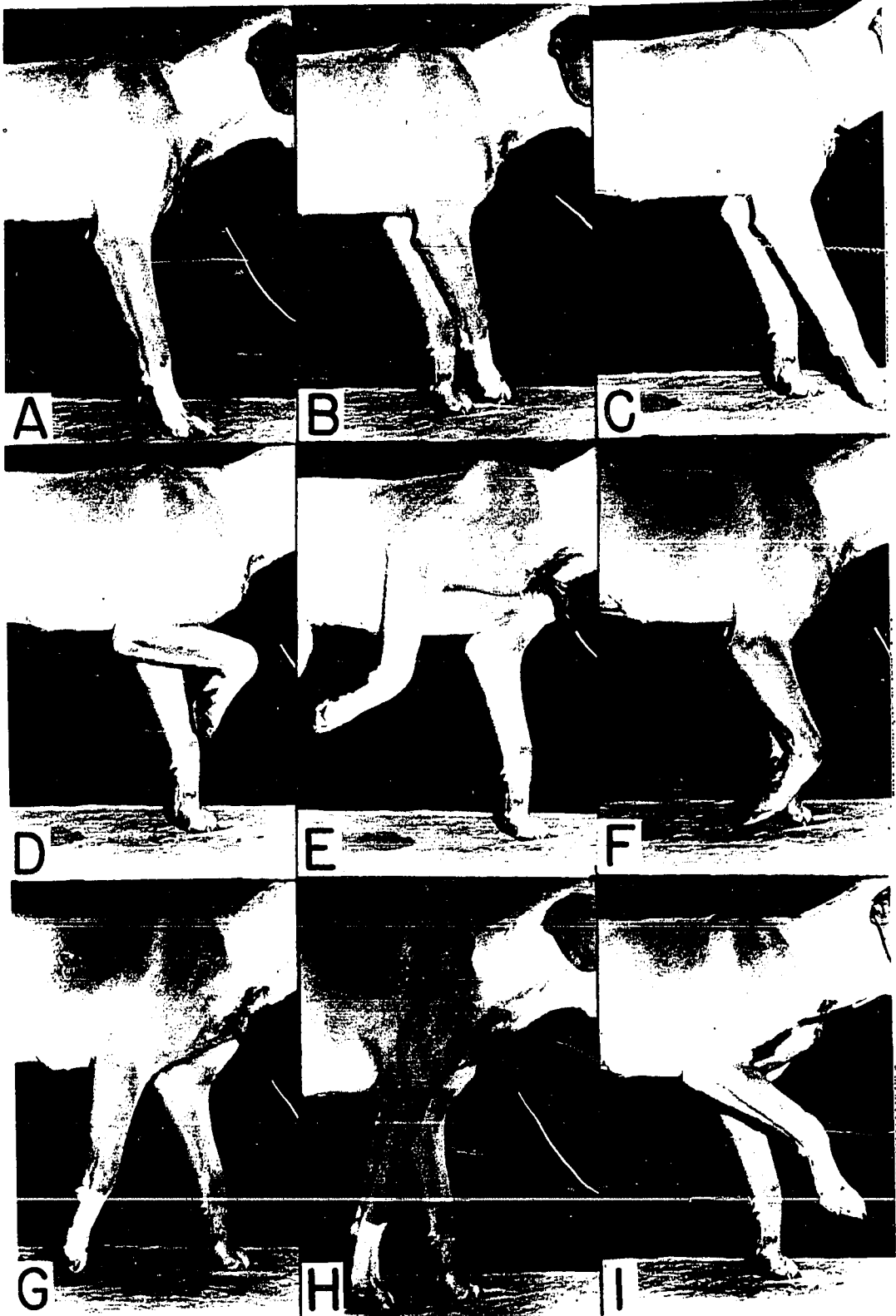


Fig. 8. Effects of faradic stimulation of the various nerves of the brachial plexus.

- A. Normal prestimulatory pose
- B. Superior radial
- C. Brachiocephalicus
- D. Musculocutaneous
- E. Axillary
- F. Thoracodorsal
- G. Deep pectoral-lateral thoracic trunk
- H. Median-ulnar trunk

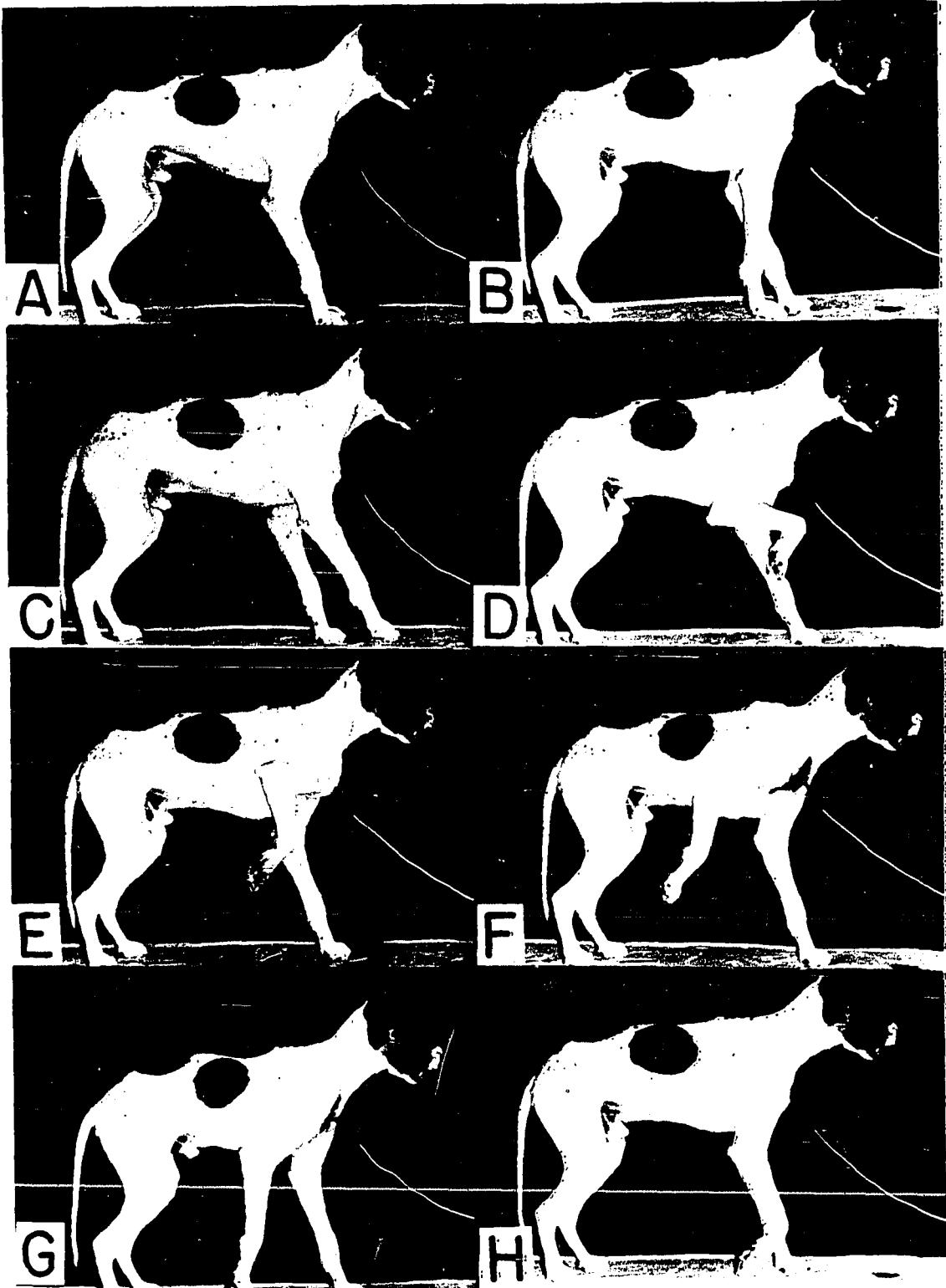
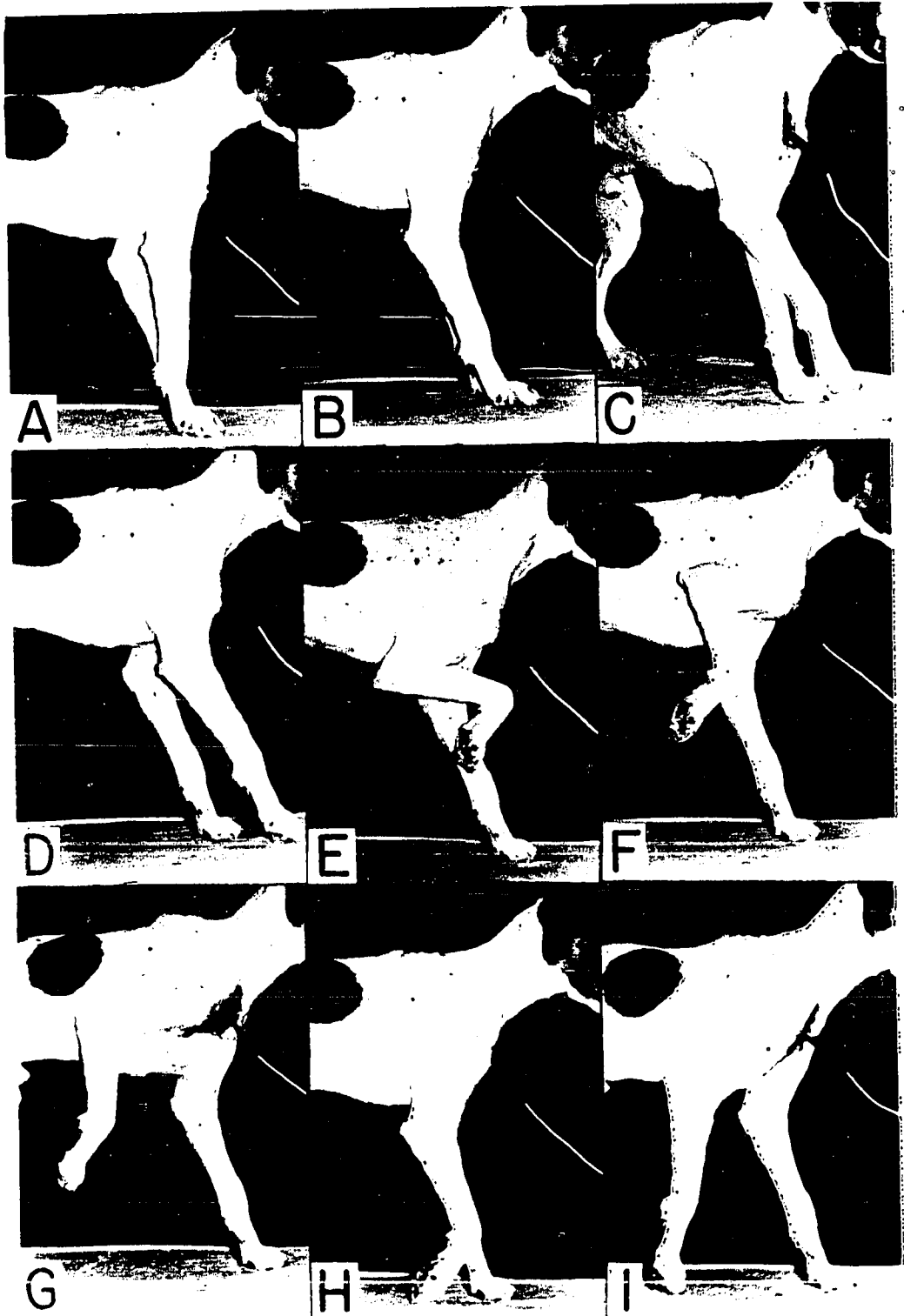


Fig. 9. Close up of animals illustrating the effects of faradic stimulation of the various nerves of the brachial plexus.

- A. Suprascapular
- B. Normal prestimulatory pose
- C. Superficial pectoral
- D. Brachiocephalicus
- E. Musculocutaneous
- F. Axillary
- G. Thoracodorsal
- H. Median-ulnar trunk
- I. Deep pectoral-lateral thoracic trunk



The flexion of the carpus was passive to some extent, however, the carpus could not be extended by manual manipulation during stimulation. The flexion of the carpus may be passive due to tension on the flexor tendons and relaxation of the extensor tendons. The musculocutaneous nerve furnishes motor supply to the biceps brachii and brachialis muscles. The biceps brachii crosses the anterior surface of the shoulder joint and should be capable of extending the shoulder joint, but even when the elbow was kept from flexing, the shoulder did not tend to flex. See Fig. 6C, 7D, 8D and 9E.

6. Axillary nerve

Stimulation caused the shoulder joint to be severely flexed and the elbow to be abducted, while the carpus was rotated inward. Again the carpal joint was slightly flexed due to slight tension on the flexor tendons. The axillary nerve supplies the teres major and minor, subscapularis (in part) and the deltoideus muscles. It will be of interest to note the position the foreleg is held when examining the various neurectomies and compare the various positions. See Fig. 8E and 9F.

7. Superior radial nerve trunk

Stimulation caused the shoulder to be slightly flexed, and the elbow, carpal and digital joints severely extended. The toes were also splayed. The entire foreleg was drawn caudally as shown in Fig. 6D

and 7H. The radial nerve furnishes motor innervation to the triceps brachii (four heads) and extensors of the carpus and digits. The long head of the triceps brachii originates on the caudal angle of the scapula and inserts on the olecranon process of the ulna. Contraction would tend to flex the shoulder joint by reason of the muscular attachments. The radial nerve is the only nerve supplying the extensors of the elbow joint including the tensor fascia antibrachii and anconeus muscles, therefore the dog should not be able to support weight if the nerve were destroyed.

8. Inferior radial nerve trunk

Stimulation caused the elbow joint to be flexed, the carpus to buckle dorsally and the digits to be over extended or in extreme dorsal flexion. It is interesting to note that the flexion of the elbow takes place only when the antagonists are not functioning. Therefore, the inferior radial nerve trunk must be recorded as a flexor of the elbow joint in cases of musculocutaneous nerve damage. See Fig. 6E and 7I. Note the splaying of the toes and dorsal buckling of the carpal joints.

9. Thoracodorsal nerve

Stimulation caused the shoulder joint to be flexed and the humerus to be pulled dorsally and caudally. The elbow and carpal joints dangled without any tonus. The thoracodorsal nerve furnishes motor innervation to the latissimus dorsi muscle, which takes its origin from the

spinous processes of the lumbar and last seven thoracic vertebrae and the last two ribs and inserts via the medial fascia of the arm to the teres tuberosity on the medial upper third of the humerus. Thus the muscle sweeps from a caudal-dorsal to an anterior ventral direction. It is an important muscle of locomotion. See Fig. 6F, 7E, 8F and 9G.

10. Median-ulnar nerve trunk

Stimulation caused the flexion of the carpal and digital joints and a slight flexion of the elbow joint. One would hypothesize that because of the flexor attachment on the flexor epicondyles of the humerus that extension would be the possible reaction. Such action cannot be elicited upon faradic stimulation of the median-ulnar nerve trunk. The median nerve supplies the pronator teres, pronator quadratus, flexor carpi radialis, superficial digital flexor and the entire radial head of the deep digital flexor. The ulnar nerve innervates the flexor carpi ulnaris, lumbricales, interossei and special digital muscles in the paw. It shares the innervation of the ulnar and humeral heads of the deep digital flexor with the median nerve.

11. Deep pectoral-lateral thoracic nerve trunk

Stimulation caused the elbow to be drawn caudally and close to the trunk. It caused only slight flexion of the shoulder joint; however, the point of the shoulder was drawn caudally. See Fig. 6G, 7G, 8G and 9I.


Another observation seen upon stimulation of the lateral thoracic nerve was the contraction of the protractor prepuce muscle. This was not suspected in the dog until noted on this investigation. Fig. 10C illustrates the penis and prepuce in the prestimulatory position. Fig. 10D-F illustrates the effects of faradic stimulation of the deep pectoral-lateral thoracic trunk on the preputial muscle.

12. General observations on stimulation of the brachial plexus


After the nerves of the brachial plexus were photographed with the limb in the normal standing position, the blood vessels were ligated and the entire plexus traced out quickly but carefully. Stimulation of the coracobrachialis nerve caused contraction of the coracobrachialis muscle and feeble flexion of the shoulder joint. The anastomotic branch between the musculocutaneous and median nerves (see Figs. 3, 4, 5 and 6) was stimulated. It caused flexion of the carpus and digits. The musculocutaneous nerve was severed below the anastomotic branch and stimulated again with the same results. The median was sectioned just proximal to the junction with the anastomotic branch, and the musculocutaneous nerve was stimulated with the same results, flexion of the carpus and digits. The anastomotic branch between the musculocutaneous and median nerves contain motor fibers that overlap the motor innervation from the median nerve to the flexors of the carpus and digits. This latter fact explains the flexion of the carpus and digits (Fig. 7D and

Fig. 10. Distant and close up illustration of the effects of faradic stimulation of the deep pectoral-lateral thoracic nerve trunk:

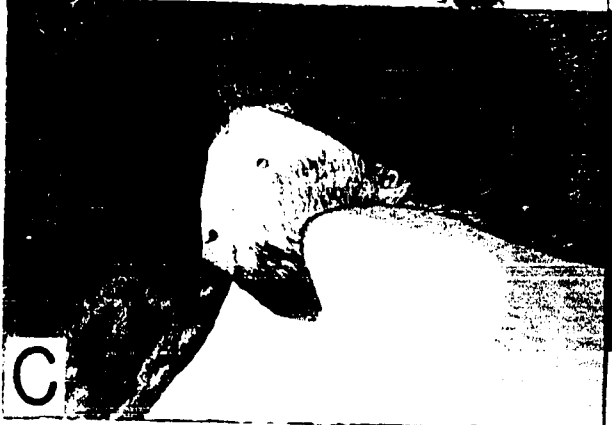
- A. Normal prestimulatory position
- B. Effects of stimulating the deep pectoral-lateral thoracic trunk
- C. Normal position of the penis and prepuce before faradic stimulation
- D. Effect on protractor prepuce muscle of faradic stimulation of deep pectoral-lateral thoracic nerve trunk
- E. Note protraction of prepuce
- F. Note elbow is drawn back and prepuce is protracted



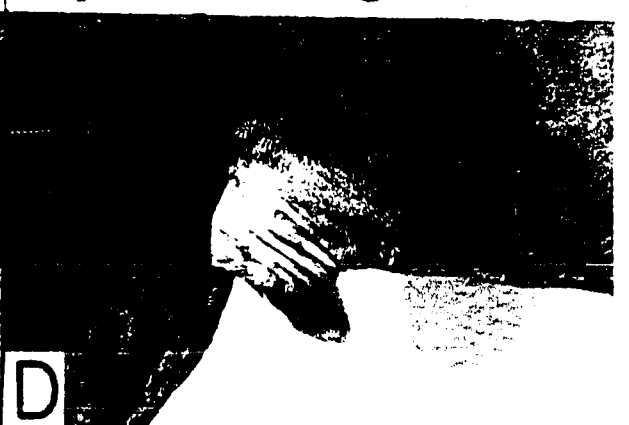A



B



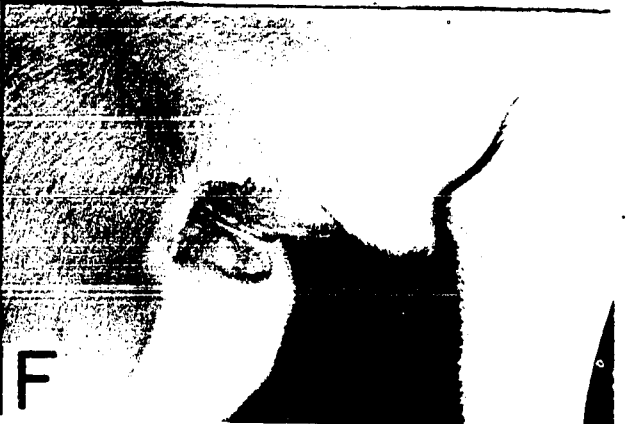C



D



E



F

9E) when the musculocutaneous nerve is stimulated.

C. Effects of Resection of the Various Individual Nerves of the Brachial Plexus

1. General considerations and clinical aspects

The "radial nerve paralysis" syndrome manifests itself in many different ways. Patients presented to clinics and private veterinarians were examined extensively using slow motion and still photographic techniques. The many different abnormal gaits presented indicated the multiplicity of the number of nerves and combination of nerves that could be affected in such a syndrome. Postmortem examinations, by the author, of very serious cases of brachial plexus involvement indicated that the affection in some instances is due to avulsion of the spinal nerves from the spinal cord. Fig. 11 depicts a patient presented to the Stange Memorial Clinic at Iowa State College, showing symptoms of brachial plexus damage. The dog, a golden retriever, was hit by a car on November 9, 1955. The motion pictures and still (Fig. 11) were taken November 16, 1955. The animal was observed for another week without any improvement in the condition. It could place the volar surface of its paw on the ground (Fig. 11G, H) but could not support its weight on the injured limb. The typical pose was the classical textbook picture of "so-called radial paralysis" (Fig. 11A-F). The elbow was dropped and the carpal and digital joints were flexed and the dorsal

Fig. 11. Clinical case of a golden retriever displaying brachial plexus nerve damage.

Note the dropping of the elbow joint in B, C and D. Note the difference between the right paw which is bearing weight and the left volar surface of the paw which is not supporting any weight (G and H)



A



B



C



D



E



F



G



H

surface of the digits rested on the ground. The animal pushed its trunk away from the ground with its right limb and used the injured limb to balance itself and the full weight of the trunk was then placed on the uninjured limb. In the static position the injured limb looked like it was too long by several inches when compared to the uninjured limb. When the gait of the animal was examined it was noticed that the volar surface of the paw could be placed on the ground, and it seemed as if some weight was being placed on the affected limb. However, when the uninjured limb was fixed in the flexed position, the animal could not support its entire weight on the injured limb.

Fig. 12 illustrates a typical brachial plexus of a dog. The superficial and deep pectoral muscles have been transected and the axilla opened. Letter A indicates where the musculocutaneous was resected, B the axillary, C the radial, D the median-ulnar and letter E indicates where the thoracodorsal nerve was resected. The deep pectoral-lateral thoracic trunk, Fig. 12 number 13, was resected just distal to the number 13 shown in the figure. The suprascapular and brachiocephalicus nerves were resected just distal to the anastomotic junctions from the sixth and seventh cervical spinal nerves. Fig. 13 number 12 indicates the portion of the inferior radial trunk that was resected. At least an inch of each nerve was removed with each resection.

Fig. 12. Drawing illustrating the various nerves of the brachial plexus and the areas where the various nerves were resected.

1. Fifth cervical spinal nerve
 2. Brachiocephalicus nerve
 3. Suprascapular nerve
 4. Superficial pectoral nerve
 5. Subscapular nerve
 6. Musculocutaneous nerve
 7. Coracobrachialis nerve
 8. Axillary nerve
 9. Deep pectoral nerve
 10. Superior radial nerve trunk
 11. Median-ulnar nerve trunk
 12. Thoracodorsal nerve
 13. Lateral thoracic nerve
 14. Subscapular muscle
 15. Teres major muscle
 16. Biceps brachii muscle
 17. Medial head of triceps brachii muscles
 18. Latissimus dorsi muscle
 19. Extensor carpi radialis muscle
-
- A. Site of musculocutaneous nerve resection
 - B. Site of axillary nerve resection
 - C. Site of radial nerve resection
 - D. Site of median-ulnar nerve trunk resection
 - E. Site of thoracodorsal nerve resection

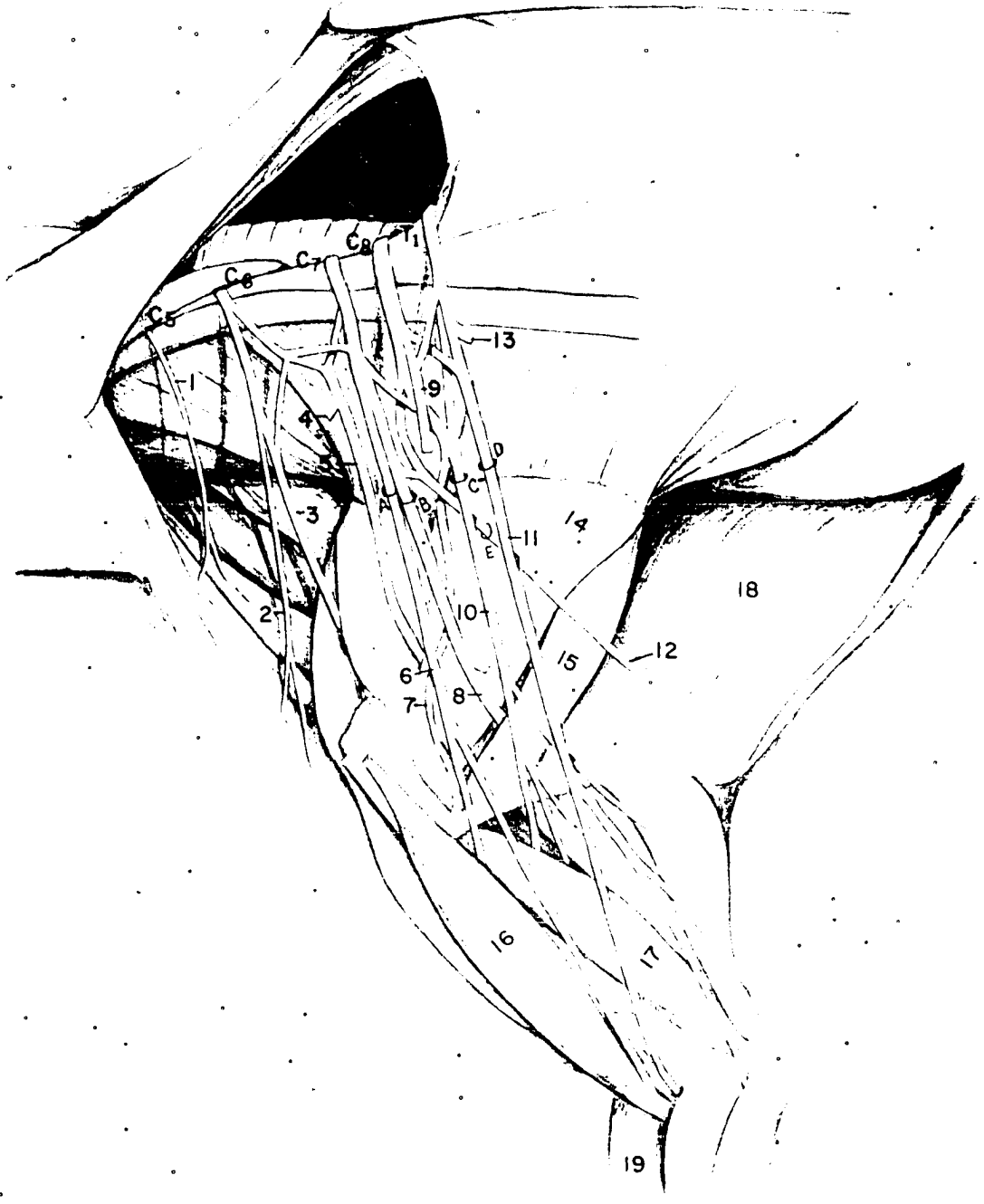
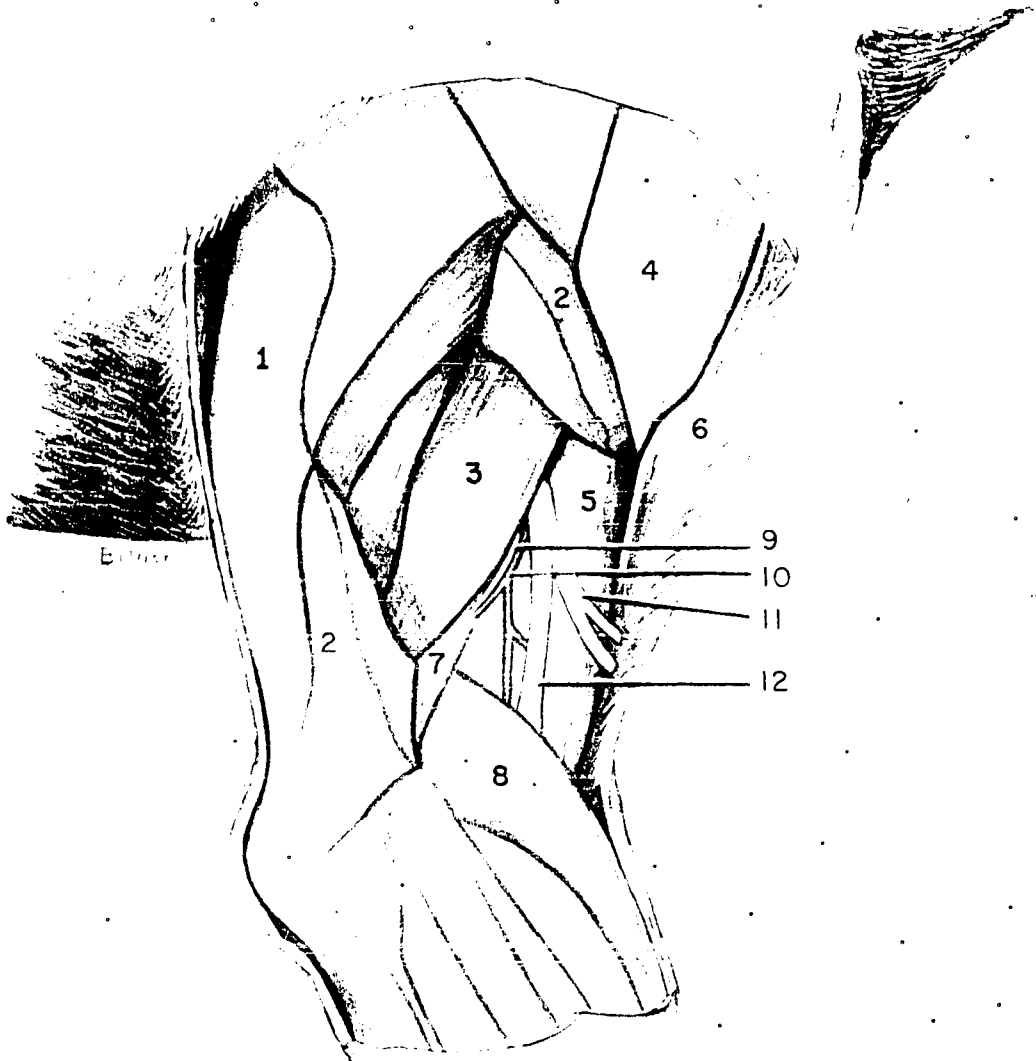


Fig. 13. Schematic drawing of the lateral aspect of the forelimb of the dog, showing the origin of the inferior radial nerve trunk.

1. Long head of triceps brachii muscle
2. Lateral head of the triceps brachii muscle
3. Accessory head of triceps brachii muscle
4. Deltoideus muscle
5. Brachialis muscle
6. Brachiocephalicus muscle
7. Humerus
8. Extensor carpi radialis muscle
9. Branch of radial nerve to triceps brachii
10. Collateral radial artery
11. Cutaneous branches of inferior radial nerve
12. Inferior radial nerve, muscular branch



2. Musculocutaneous nerve

The musculocutaneous nerve was resected on three dogs. There was no noticeable lameness caused by the loss of the musculocutaneous nerve alone. It was observed during faradic stimulation of the inferior radial nerve trunk that the extensor muscles of the carpus and digits could flex the elbow joint. The flexors of the carpus and digits also have a tendency to flex the elbow joint.

3. Axillary nerve

The axillary nerve was resected on three dogs. There were no noticeable symptoms caused by the lack of the major flexor muscles of the shoulder. Upon critical examination of the gait of the normal dog the shoulder is not actively flexed. However, the latissimus dorsi muscle, innervated by the thoracodorsal nerve, is also capable of flexing the shoulder joint.

4. Radial nerve

The inferior radial nerve was resected in the area of the musculospiral groove (Fig. 13). The nerve was isolated just proximal to the elbow joint between the lateral head of the triceps brachii and the brachialis muscle. Two inches of the radial nerve were removed. Seven dogs were used in the inferior radial nerve resections. Six of the seven dogs did not show any symptoms after the effect of trauma had subsided,

one dog knuckled over on the dorsal surface of the digits for a few days, but by the tenth day after resection they all had learned to flip the carpus out in such a manner as to always position the volar surface of the paw on the ground. The reflex flipping of the paw on the injured side could not be distinguished from that on the uninjured side. Normal animals flip the carpus and digits forward in the same manner. After the tenth day no symptoms could be detected in the dogs with inferior radial nerve resection.

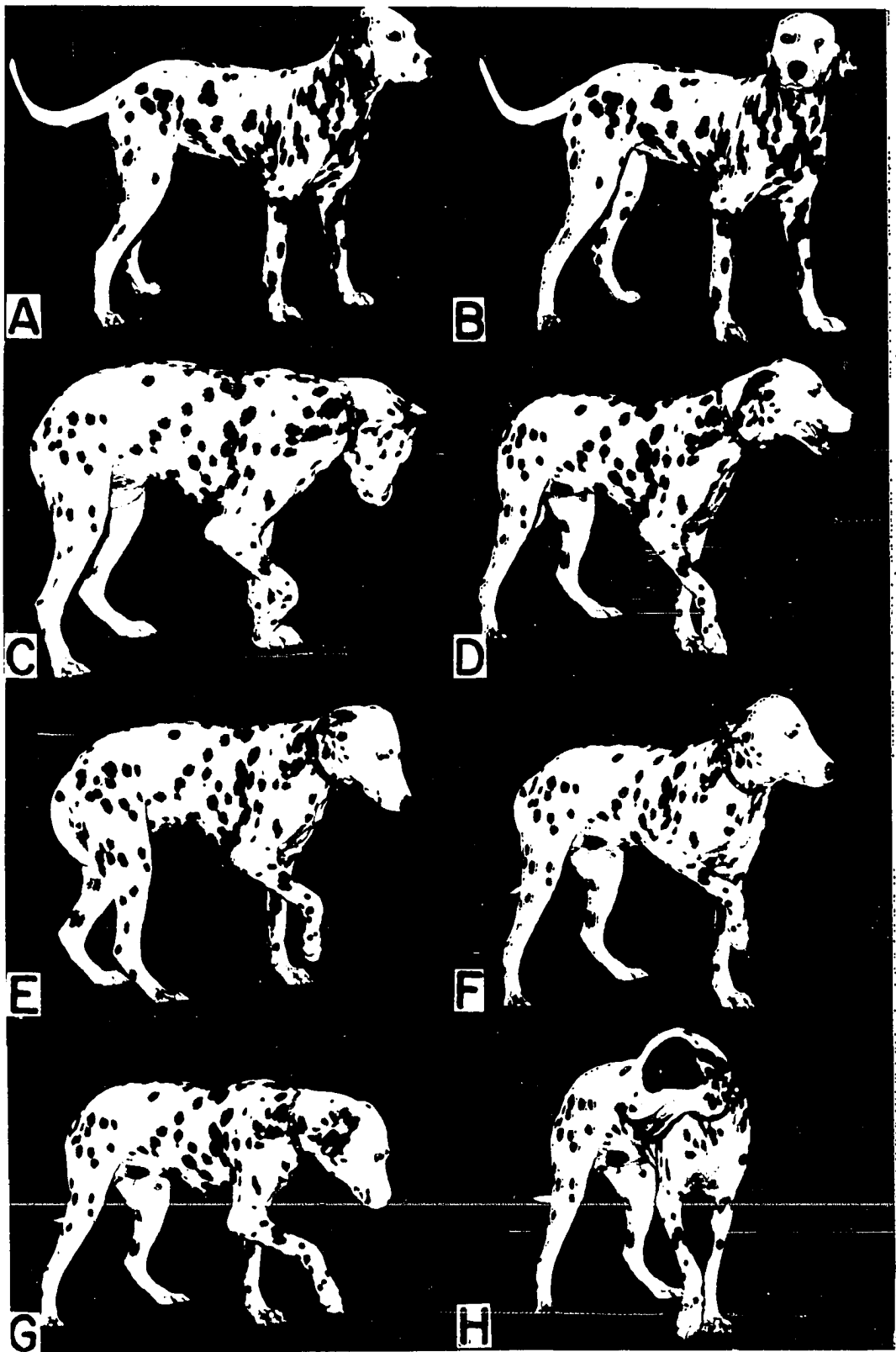
The superior radial nerve trunk was resected in six different dogs. It was performed just distal to the origin of the radial nerves from the seventh and eighth cervical and first thoracic spinal nerves. The loss of this portion of the radial nerve caused severe symptoms. The dog was unable to support its weight on the affected side. Ten days after resection, the flexor tendons of the carpus and digits started to contract. The dog could still place the volar surface of the paw on the ground, but the elbow was dropped and the limb could not be extended. The normal tonus in the biceps brachii and brachialis muscles caused the elbow to be flexed almost continually. It is interesting to note that the loss of the radial nerve alone did not produce the same syndrome as was noted in the typical clinical case illustrated in Fig. 11. Fig. 14A and B illustrates the static position of the dog when the inferior radial trunk was resected. Note the manner in which weight is

Fig. 14. Resection of the radial nerve trunks.

A-B. Effects of resection of the inferior
radial nerve trunk

C-H. Effects of resection of the superior
radial nerve trunk

Note the characteristic position the
forearm is carried in F. This position
will be compared to that position found
after resection of both the superior radial
and musculocutaneous nerves.



borne by each front limb. Fig. 14C-H illustrate the typical position of the animal when the superior trunk was resected. Note Fig. 14C and D show the dropping of the elbow and buckling of the carpal joints, while E and F show the effects of contraction of the flexors of the elbow. Clinical cases were noted where the patient carried its foreleg in a similar manner to that shown in Fig. 14F.

5. Median-ulnar nerve trunk

The median-ulnar trunk was resected on three animals. There was no recordable signs of lameness in the gait of the animals. There was a slight increase in the over extension or dorsi flexion of the carpus in the standing position. The muscles that were denervated did not atrophy as badly nor were there any signs of tendon contractions. When the animals were held up off the ground with the operator's hands cupped under the fore arm, spontaneous contractions of some of the flexor muscles could be felt when the animals weight was shifted from side to side. It should be noted that there is an anastomotic branch from the musculocutaneous nerve that joins the median nerve a few centimeters proximal to the elbow joint, and that faradic stimulation of this anastomotic branch caused contraction of the flexors of the carpus and digits. This explains the lack of atrophy and the ability of the animal to control some of the flexor muscles of the carpus and digits.

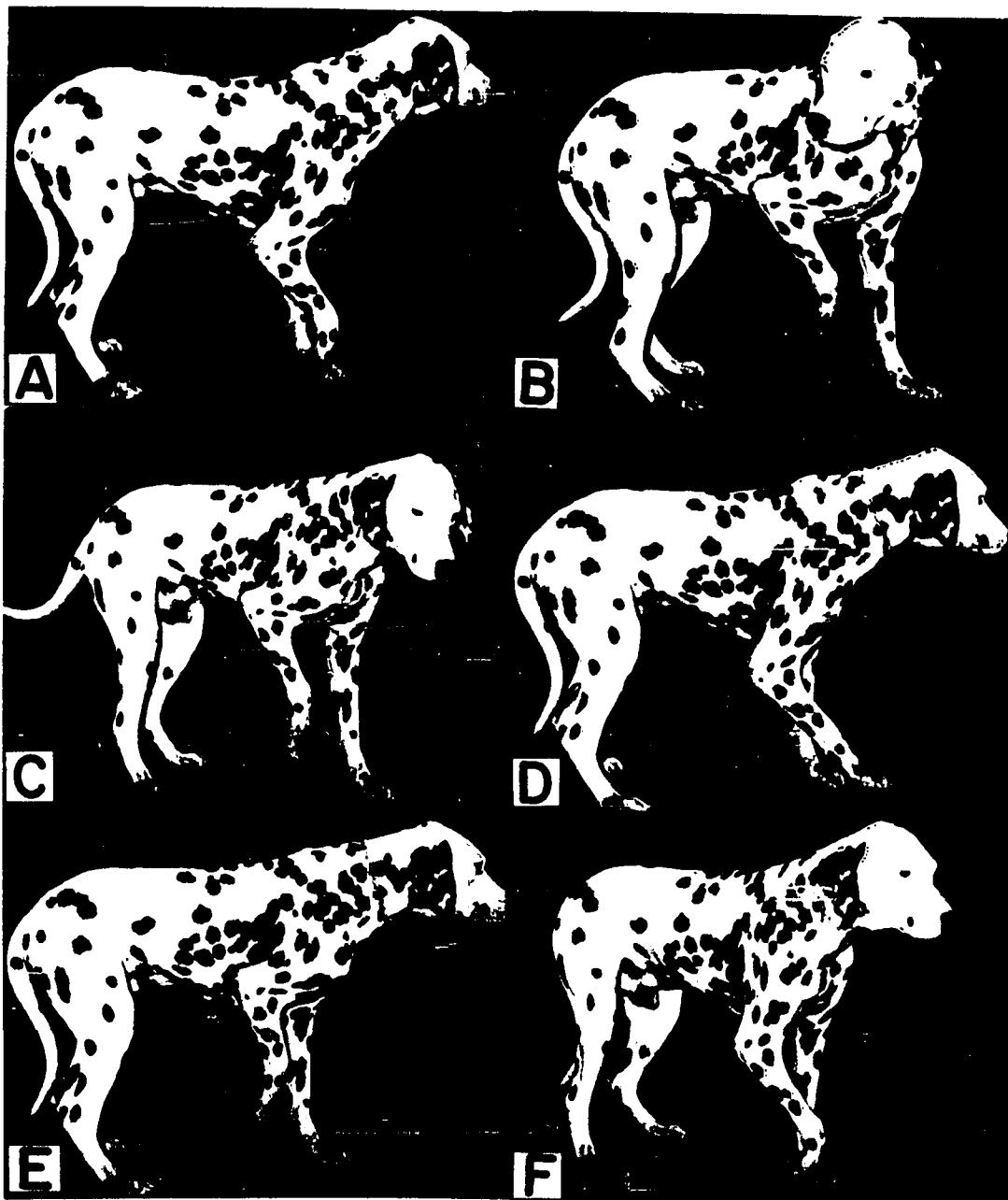
D. Effects of Resection of Various Nerve Groups in the Brachial Plexus

1. Superior radial and musculocutaneous nerves

The superior radial trunk and the musculocutaneous nerves were resected on six different animals. The superior radial nerve innervates the extensors of the elbow and the extensors of the carpus and digits. The musculocutaneous nerve innervates the flexors of the elbow. The flexor tendons of the carpus and digits contract due to the fact that there is no antagonist muscles working against them. This is responsible for a slight fixed flexion of the elbow. In the walking or running gaits of the animal the elbow is not flexed, but the brachiocephalicus muscle draws the leg forward and it is dropped to the ground with the volar surface of the paw on the ground, but bearing no weight. The elbow can be dropped and often is (Fig. 15A, D and F) when the animal is at rest. However, the characteristic pose seen in Fig. 14F when the superior radial nerve alone is resected does not occur. When the paw is held off of the ground the axillary or thoracodorsal nerves innervating the flexors of the shoulder, pull the leg caudally and the forearm hangs almost perpendicular to the surface of the ground (Fig. 15E, 16C and 17A, D and F). When the flexors of the shoulder are relaxed the elbow is dropped and the characteristic pose for "radial paralysis" can be noted. However, the symptoms do not correspond to the usual syndrome of

Fig. 15. Effects of resection of the superior radial and musculocutaneous nerves.

Note the position of rest, A, D and F. This resembles clinical cases of the affection, however, the animal is able to lift the paw off the ground. Note that the forearm is held nearly perpendicular to the surface of the ground, C and E. The volar surface of the paw can still be placed upon the ground, letter D.



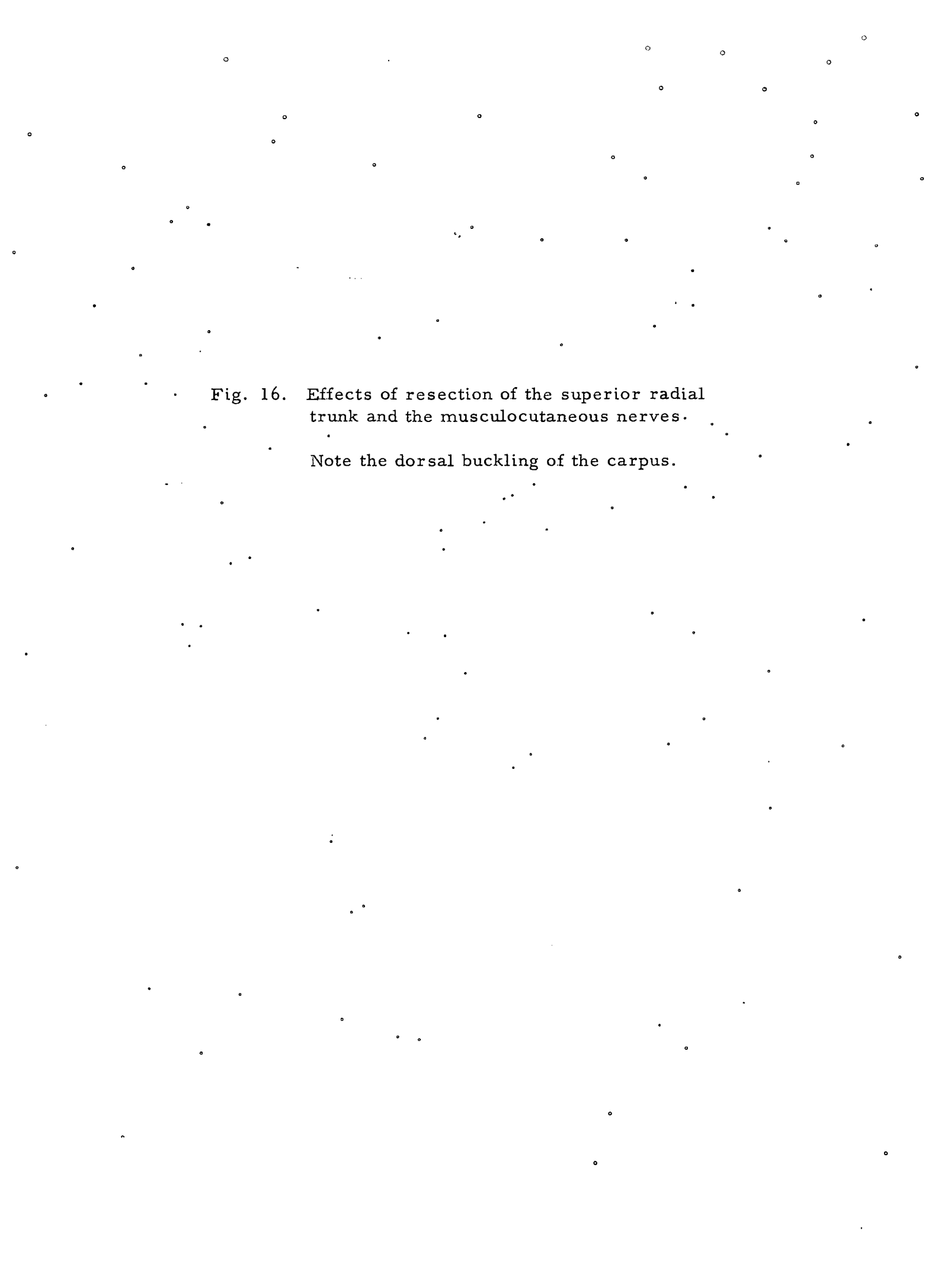



Fig. 16. Effects of resection of the superior radial trunk and the musculocutaneous nerves.

Note the dorsal buckling of the carpus.



Fig. 17. Effects of resection of the superior radial and musculocutaneous nerves.

Note that the paw is rested on the surface of the ground on the toes, it will then knuckle over onto the dorsal surface of the digits.



"radial paralysis".

2. Superior radial and thoracodorsal nerve

Two dogs were used for this experiment. The symptoms noted were exactly the same as those seen when the superior radial nerve trunk was resected.

3. Musculocutaneous and thoracodorsal nerves

Two dogs were used for this experiment. It was impossible to note any symptoms when the dog was walked or trotted (Fig. 18A-D).

4. Superior radial, musculocutaneous and thoracodorsal nerves

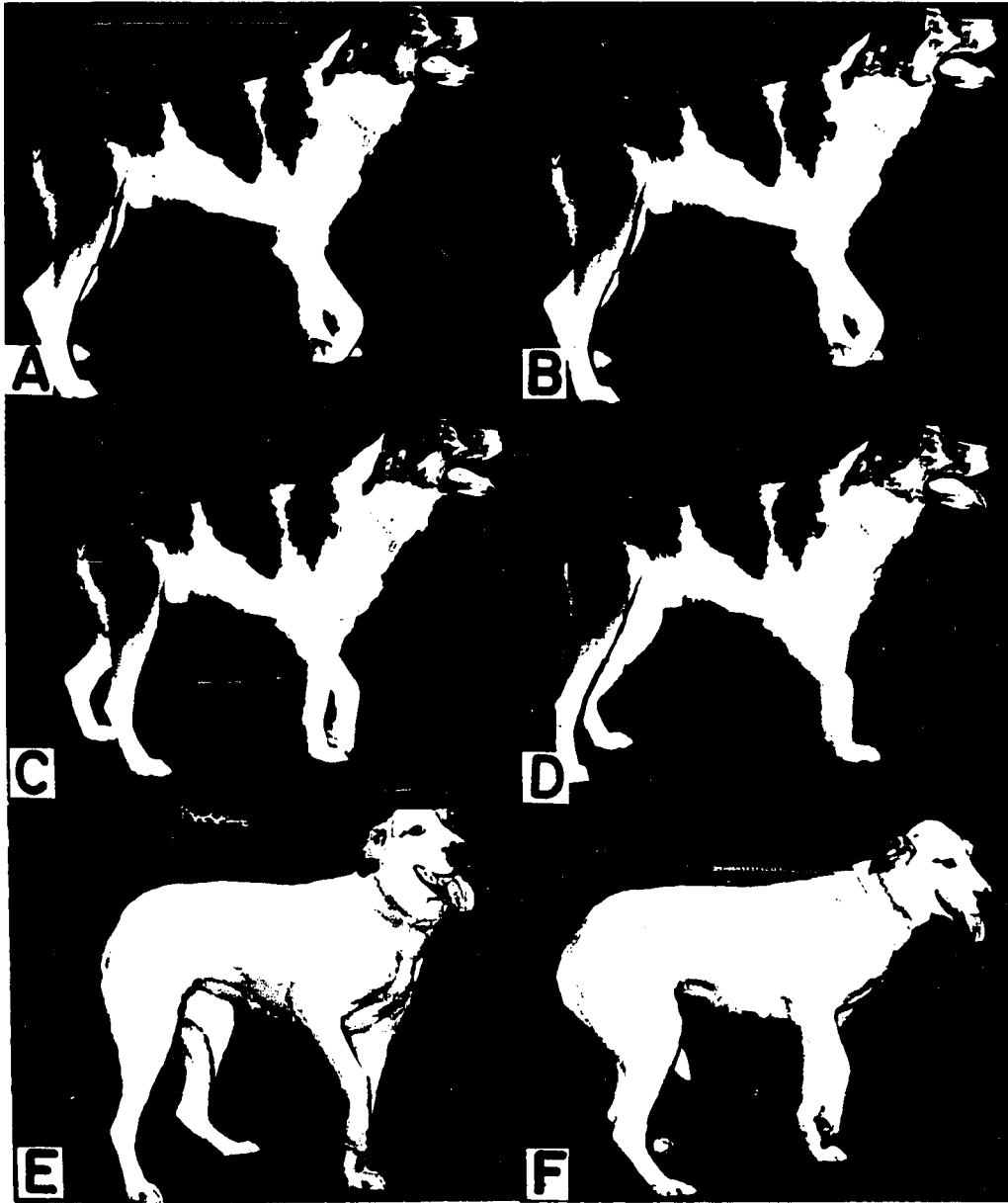
Three dogs were used for these neurectomies. It was very obvious that the flexors of the shoulder were lifting the leg from the ground and that the brachiocephalicus muscle was advancing the entire limb as far forward as possible. The brachiocephalicus muscle could not advance the limb beyond the anterior margin of the pectoral muscles. Therefore, the normal stride was reduced considerably. This lag is probably due to the fact that the intrinsic muscles of the leg were not extending the limb in the normal manner. The elbow was slightly flexed and the carpus and digits dangled loosely. The axillary and brachiocephalicus nerve, through the muscles they innervate, kept the limb from dragging on the surface of the ground. The volar surface of the paw rarely is placed on the surface of the ground. It generally just barely strokes the surface

Fig. 18. Effects of combined neurectomies on various nerves of the brachial plexus.

A-D. Superior radial and thoracodorsal nerves

E-F. Radial, musculocutaneous and thoracodorsal nerves

Note the resting position in pictures A and B. Note that the elbow is flexed in C and D, however, the shoulder has to be flexed in E and F to keep the paw off the ground.



of the ground. The elbow was turned outward similar to that seen when the axillary nerve was faradically stimulated, and the leg was pivoted outward as the entire foreleg is drawn forward with the shoulder joint flexed.

There was an abnormal cord-like structure extending from the olecranon to the caudal border of the scapula. It was very prominent when the supraspinatus and infraspinatus muscles extended the shoulder joint. The flexors hold the shoulder in a flexed position and the forearm hangs perpendicular to the ground.

The stasis position of the affected forelimb seems to resemble the radial and musculocutaneous neurectomies.

5. Radial, musculocutaneous, axillary and thoracodorsal nerves

These neurectomies were performed on two different dogs. The brachiocephalicus muscle practically picks up the entire leg and draws it forward (Fig. 20E). Contraction of the brachiocephalicus muscle caused passive flexion of the shoulder joint because of the muscle attachment to the anterior edge of the humerus. The affected leg otherwise dangles without much control from the shoulder joint. The brachiocephalicus, omotransversarius and deep pectoral muscles hypertrophy very rapidly due to the tremendous strain placed upon them.

The volar surface of the paw can still be lightly placed on the

Fig. 19. Effects of combined superior radial, musculocutaneous and thoracodorsal neurectomies.

Note how the toes are placed on the surface of the ground B and G. Also how they may knuckle over onto the dorsal surface of the digits (C, D, E and F).



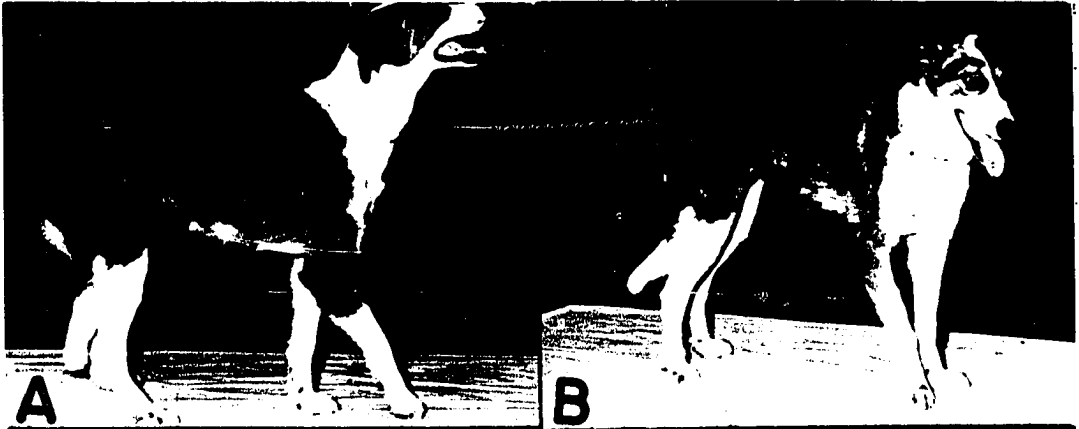


Fig. 20. Effects of combined neurectomies performed on the superior radial, musculocutaneous, axillary and thoracodorsal nerves.

Note that the brachiocephalicus muscle lifts the entire limb in the picture lettered E. The paw rests lightly on the surface of the ground and always seems to be too long so that it is resting in advance of the leg that is supporting the weight.



surface of the ground. The elbow and carpal joints are held in a slightly flexed position. The shoulder joint is extended slightly by the supraspinatus and infraspinatus muscles as the leg reaches its farthest anterior position. However, no weight can be borne by the leg. A cord-like structure was seen stretching between the olecranon and the caudal border of the scapula (Fig. 20).

6. Superior radial, musculocutaneous and median-ulnar trunk

Three dogs were used for these combined neurectomies.

The brachiocephalicus muscle advanced the leg, but the entire dorsal surface of the digits and carpus was drawn along the surface of the ground. No attempt was made by the animal when walking to extend the carpus and digits. Therefore, the dorsal surface of the digits soon became abraded. The elbow remained in a semiflexed position due to contraction of the extensor and flexor tendons. The contraction of the flexor muscles of the shoulder caused the shoulder to be carried forward in a flexed position. The brachiocephalicus muscle advanced the leg as far forward as the level of the thoracic inlet. The leg always seemed to be placed on the ground caudal to where it should have been dropped. No weight was placed on the affected leg.

The latissimus dorsi muscle, innervated by the thoracodorsal nerve, aids in flexing the shoulder joint. The latissimus dorsi and deltoideus muscles stand out prominently every time the animal moves

the injured limb. The carpus and digits dangle without any control (Fig. 21).

Fig. 22 illustrates a comparison between a radial, musculocutaneous and median-ulnar neurectomy and a clinical patient exhibiting brachial plexus damage. There are many similarities, but the patient could not lift its foreleg as the experimental subject was able to do. Fig. 22D and F.

7. Radial, musculocutaneous, median-ulnar and axillary nerves

These combined neurectomies were performed on two dogs. The characteristic gait of the animal was to walk on the dorsal surface of the carpus and digits (Fig. 23A-D). The brachiocephalicus muscle along with the omotransversarius muscle advance the limb and elevate it slightly, but the dog was never seen to place the volar surface of the paw on the ground. Fig. 23A-D illustrates the typical position assumed by this animal. In many ways it matches the clinical case of brachial plexus damage, in other instances it seems much more severe. The elbow remained dropped and the leg appeared several inches too long when compared to the normal limb. Continual contact of the dorsal surface of the paw with the ground soon caused an ulcer to form. The flexor tendons soon contracted so that the carpus could not be extended, even manually.

Fig. 21. Effects of combined resection of the radial, musculocutaneous and median-ulnar nerves.

The typical position is similar to that seen in the neurectomies performed on the radial and musculocutaneous nerves. However, all sensation is absent in the area below the carpus and the animal does not know when the dorsal surface of its paw is on the surface of the ground.

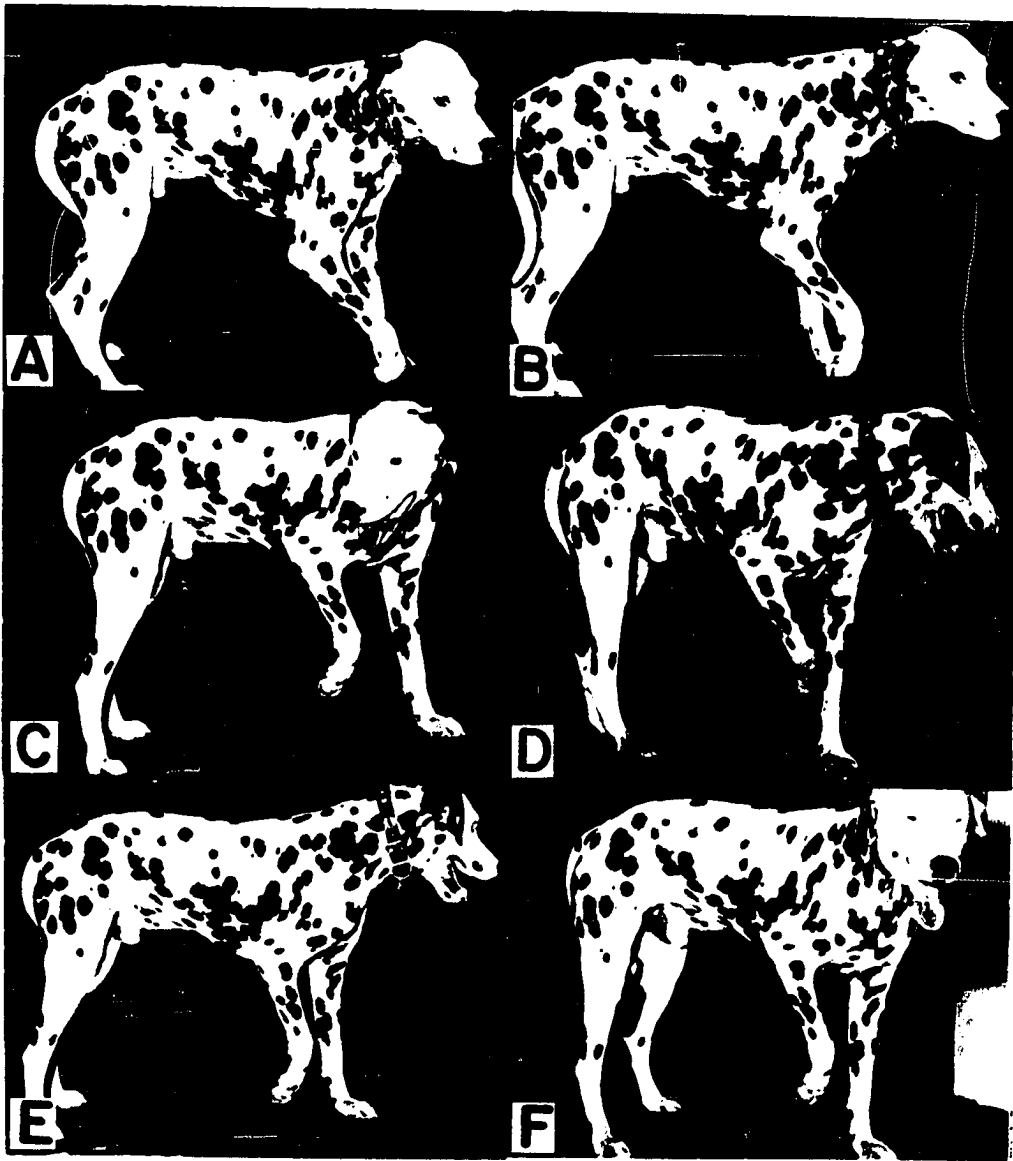


Fig. 22. Comparison between a combined radial, musculocutaneous and median-ulnar neurectomy and a clinical case of brachial plexus damage.

Note A and C resemble the resting position of the clinical patient, however, the patient could not elevate the foreleg as in D through F.






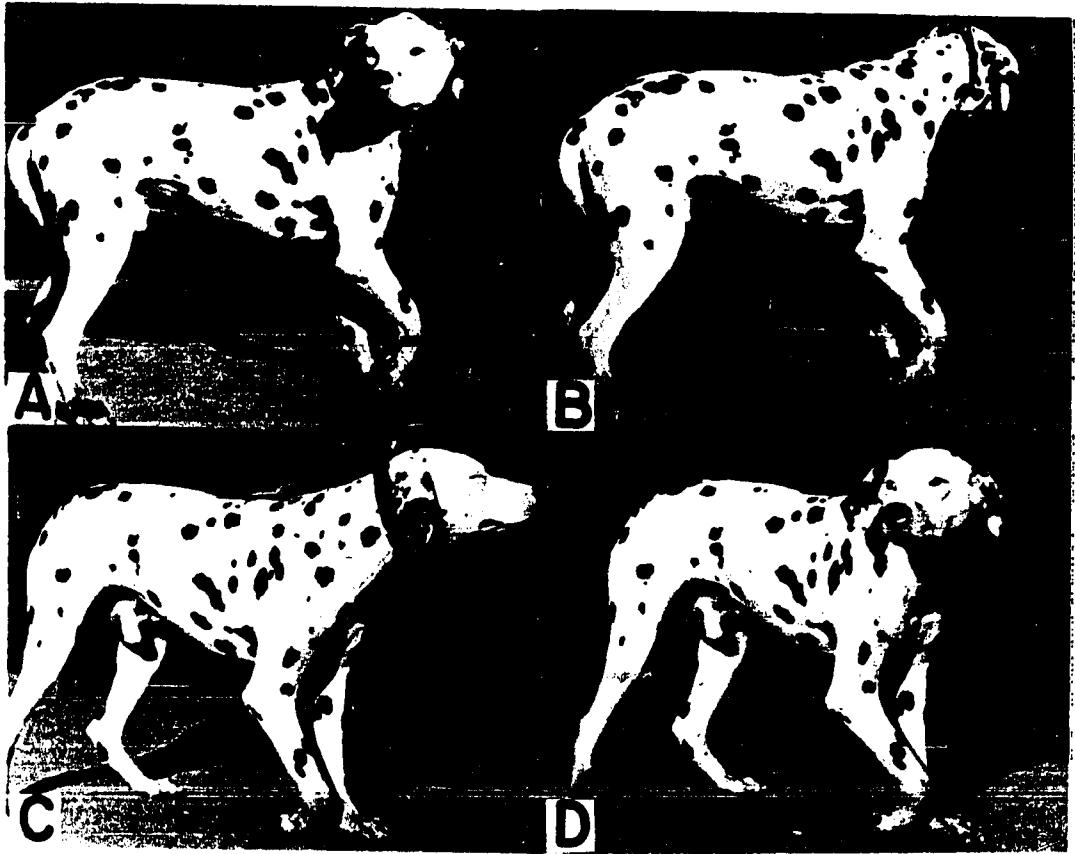


Fig. 23. Effects of resection of the radial, musculo-cutaneous, median-ulnar and axillary nerves.

This is the typical pose found in some clinical patients suffering from brachial plexus damage. However, in some ways it appears more severe as the experimental dog continued to drag the dorsal surface of the carpus, and only in very severe clinical cases where the spinal nerves are avulsed from the cord does one find similar symptoms.



8. Radial, musculocutaneous, thoracodorsal, lateral thoracic and axillary nerves

Two dogs were used for the resection of these nerves. The brachiocephalicus muscle continues to draw the leg forward. The leg dangles out of control from the shoulder joint distally. The supraspinatus and infraspinatus muscles were able to extend the shoulder joint as the brachiocephalicus and omotransversarius muscles advanced the limb. The volar side of the paw was dropped heavily onto the ground and as the dog advanced the affected limb, the elbow joint was passively flexed and the act of advancing the lifeless limb was repeated. The animal was able to hold the affected limb off of the ground for short periods of time by contraction of the brachiocephalicus and omotransversarius muscles, otherwise it jounced and bounced along wherever gravity dictated.

The elbow joint was fixed in a slight flexed position and the carpus just flopped uselessly first on the dorsal surface and then on the volar surface.

The static poses do not indicate the severity of the affection. Fig. 24B illustrates the knuckling over of the carpus and digits. However, the other views illustrated do not appear as severe as the previously demonstrated neurectomies.

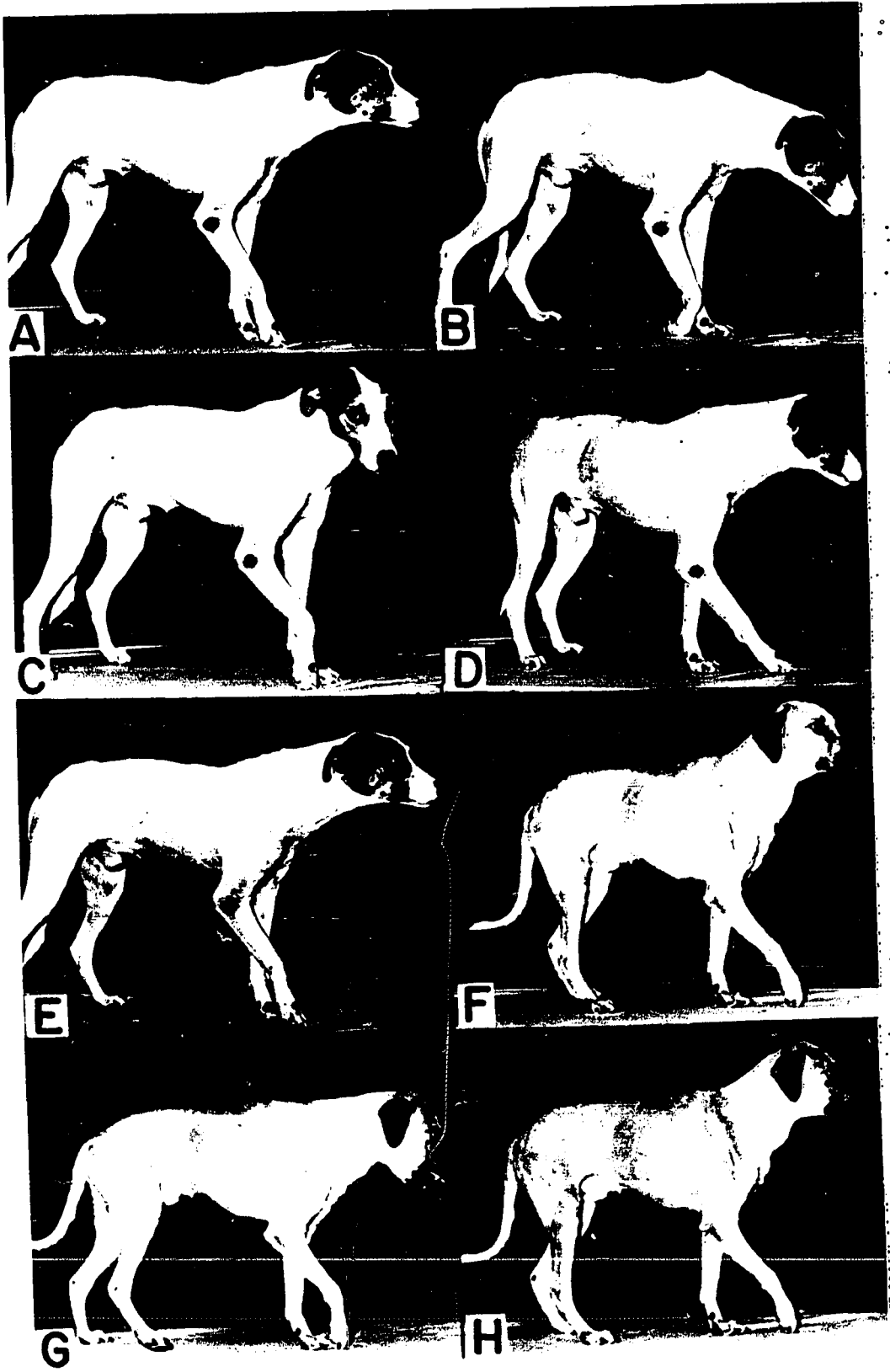
Fig. 24. Effect of resection of certain groups of nerves in the brachial plexus.

A-E. Radial, musculocutaneous, thoracodorsal, lateral thoracic, and axillary nerves

F-H. Radial, musculocutaneous, thoracodorsal, lateral thoracic, axillary, suprascapular and brachiocephalicus nerves

Note the relative absence of severe contraction of the tendons, this is explained by the fact that there are no antagonists to any joint below the shoulder. The normal muscular tonus present in normally innervated muscles causes tension at all times on their respective tendons, even when the animal is asleep.

Note the prominence of the spine of the scapula in pictures lettered F-H. Atrophy of the supraspinatus and infraspinatus muscles causes this prominence to be visible.



9. Radial, musculocutaneous, thoracodorsal, lateral thoracic, axillary, suprascapular and brachiocephalicus nerves


One dog was used for this series of neurectomies. The leg dangled like it was on a weak screen door spring, or a long rubber band, completely out of control. It was pivoted first one way and then another, depending on how the paw struck the ground. The omotransversarius muscle was too weak to draw the leg forward by itself. However, it could be seen to contract each time the leg was supposed to be advanced. There was no muscular activity below the shoulder joint. The spine of the scapula was already very prominent ten days after the neurectomies were performed. The elbow and carpus were fixed in a slightly flexed position. The shoulder joint allowed the leg to pivot in every direction. It was remarkable that the dog could keep the affected leg from dragging on the ground, as was seen with dogs with a less severe affection. The affected limb often collided with the normal opposite limb and was jounced laterally at an acute angle. This animal exhibited symptoms that were much more severe than any clinical case so far observed by the present author. The static pose, Figs. 24E-H and 25A-E, illustrate typical position assumed by the animal while at rest. It will be noted that the paw is often partially supinated, rotated so that the volar surface of the paw is directed medially (Fig. 25B and D). This animal does not show much contraction of the tendons of the carpus and digits. However, the elbow is fixed in a slightly flexed position.

Fig. 25. Effects of neurectomies performed on certain groups of nerves in the brachial plexus.

A-E. Radial, musculocutaneous, thoracodorsal, lateral thoracic, axillary, suprascapular and brachiocephalic nerves

F-I. Radial, musculocutaneous, thoracodorsal, lateral thoracic and axillary nerves

Note the atrophy in the angle formed by the humerus and scapula in picture B. This area of the triceps is made even more prominent by the atrophy of the infraspinatus muscle.



E. Effects of Resection of the Last Three Cervical and First Thoracic Spinal Nerves

1. Cervical six and seven

Two dogs were used for this series of neurectomies. The animal did not advance the limb far enough forward for a normal pace. Therefore a longer step was taken with the left forelimb and a shorter step was taken by the affected limb. The elbow joint was pivoted so that the point of the elbow was abducted. The paw was allowed to remain on the ground for a longer period of time so that the animal seemed to run with its shoulder and elbow joints in a semiflexed position.

The spine of the scapula was prominent because of muscle atrophy on either side of the spine. The animal showed a little gallop in its stride, but otherwise it was not seriously handicapped. Fig. 26A-C illustrates the static position of an animal in which the sixth and seventh cervical spinal nerves had been resected.

2. Cervical seven and eight

Two dogs were used for this neurectomy. The dog walked and ran with a stiff leg on the affected side. The brachiocephalicus muscle advanced the leg, but the elbow joint could not be flexed so that the leg remained stiff and the dorsal surface of the digits was dragged over the ground. The affected leg could be elevated only far enough to allow

Fig. 26. Effects of resection of the spinal nerves that form the brachial plexus.

A-C. Cervical six and seven




D. Cervical eight and thoracic one

E-F. Cervical seven and eight

Note that no symptoms are evident in the static picture when the sixth and seventh cervical spinal nerves are resected.

Note that in D the animal shows the typical static picture of "radial nerve" paralysis. It cannot bear weight on the affected limb. Indicating that in this animal the seventh cervical does not supply the triceps brachii muscles.

E and F should be compared with Fig. 27.



the leg to be brought forward. Examination from an anterior-posterior position showed that the elbow was abducted as the humerus was pivoting outward at the shoulder joint. This is due to the fact that the brachiocephalicus muscle, by virtue of its medial and lateral attachments, tends to rotate the humerus outward if there are no antagonist muscles to act in keeping the humerus in line with the scapula.

The flexors and extensors of the shoulder were unable to function. The flexors of the elbow also were not functioning. There was still adequate innervation to the extensor muscles of the triceps brachii, so that the animal could bear its entire weight on the affected limb. This indicates that some of the innervation to the triceps brachii must come from the first thoracic spinal nerve (Fig. 27A-F).

The second animal exhibited a different gait from that seen with the animal in Fig. 27A-F. The second dog, Fig. 26E-F, could flex its elbow and advance its affected limb. However, it had difficulty in supporting the entire weight of the body on the affected limb. The only symptom noted was a short jump every time the affected limb was advanced. Also it exhibited a slight weakness in the shoulder joint.

3. Cervical eight and thoracic one

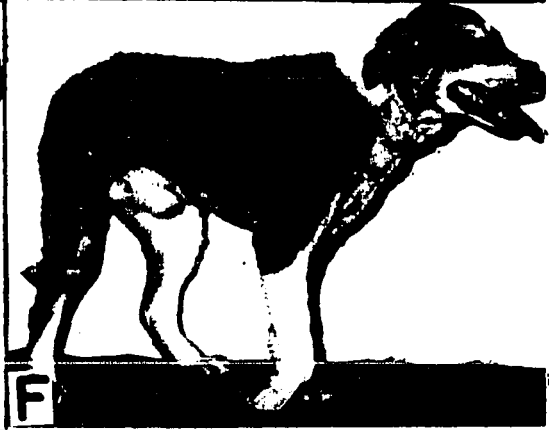



Two dogs were used for this neurectomy. The only symptom the first dog exhibited was a slight weakness on the affected side. The animal advanced with the affected shoulder and elbow joints flexed more

Fig. 27. Effects of resection of the seventh and eighth cervical spinal nerves.

Note that the dorsal surface of the paw, A, C and F, is on the surface of the ground. It is advanced from this position.

Note in picture B and E how the leg is advanced in an extended position by the brachiocephalicus muscle.

Note further in picture D that the animal can place weight on the affected limb. However, the left leg is bearing more weight than the right as evidenced by more dorsiflexion of the carpus on the left side.



than normally. It had a galloping gait. It could bear the weight of the body on the affected limb as well as the normal limb.

From a head on view, the animal showed a crossing of the right leg over the normal left leg, and the right limb was pivoted and the elbow thrown outward to advance the limb. There was a slight hitching as the affected limb was placed on the ground. No symptoms were noticeable on examination of the static position.

The second dog showed altogether different symptoms. It could advance the limb, but it could not support its weight on the affected limb. It advanced both front limbs at the same time, a very unusual gait even for a lame dog. It was able to flex the shoulder and elbow joints, but it could not extend the shoulder joint. It held the affected limb very similar to a superior radial neurectomy (Fig. 26D).

4. Cervical sever and thoracic one

Two dogs were used for this neurectomy. There was only a slight lameness noted in these neurectomies. The first dog exhibited more circumduction than normal as it swung the leg from the shoulder laterally to place it on the ground. The injured limb was placed on the ground two to three inches more laterally than normal. There seemed to be more active flipping of the carpus than normally. Fig. 28G-H illustrates the normal static pose, G, and the start of the exaggerated



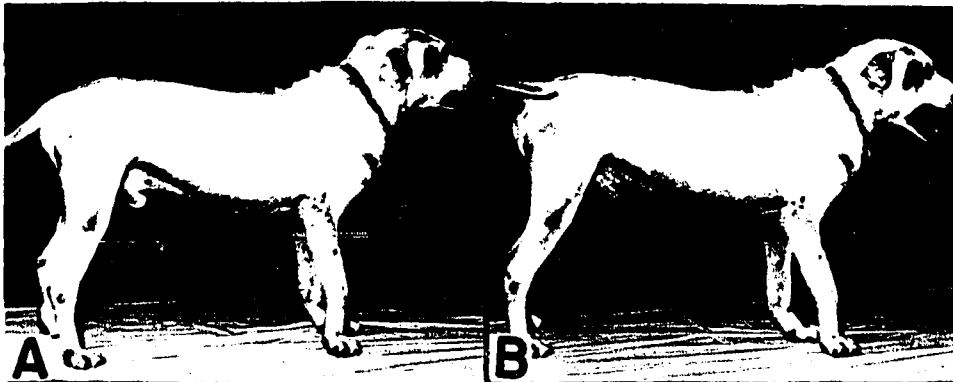
Fig. 28. Effects of neurectomies performed on the spinal nerves of the brachial plexus.

A-F. Cervical six, seven and eight

G-H. Cervical seven and thoracic one

Note the slight buckling of the carpal joints, A, B and D, indicating an inherent weakness in the muscles below the elbow joint. However, the weight of the body can be placed on the affected limb, picture C.

Note in picture G that the animal can bear the full weight on the affected limb. Note also in picture H the exaggerated circumduction.



circumduction, H.

The second dog exhibited, in addition to the symptoms shown by the first dog, a slight abduction of the elbow. No other symptoms could be noted. The animal seemed to have good control of the shoulder joint.

5. Cervical six, seven and eight

Two dogs were used with this neurectomy. The animals exhibited a rather stiff-legged gait. They could not advance the leg much beyond the anterior edge of the superficial pectoral muscles (thoracic inlet). They could not control the flexors of the elbow nor the flexors or extensors of the shoulder on the affected side. The shoulder joint was allowed to pivot too much. However, the dog was able to advance the limb half of the usual distance, and when placed on the ground the affected limb could bear the entire weight of the dog (Fig. 28C). Because the shoulder could not be controlled, the leg dangled whenever the dog ran. The normal limb took most of the weight and compensated for the short step of the affected limb by an extra hop, which lengthened the stride of the normal limb.

6. Cervical seven and eight and thoracic one

One dog was used for this neurectomy. The symptoms were very severe. The elbow was dropped, the carpus flexed and the animal placed the entire dorsal surface of the carpus and digits on the ground. The

carpus was twisted so that the toes were directed toward the opposite side (Fig. 29B and E). The leg was advanced by the brachiocephalicus muscle, but the digits were usually caught under the carpus of the normal limb. No weight was borne by the affected limb. The dorsal-lateral surface of the carpus and digits was drawn along the surface of the ground every time the animal advanced its right leg. The leg looked as if it were six inches too long when compared with the normal limb. This was due to the dropping of the shoulder joint. Fig. 29A-F illustrates the typical static position assumed by the affected limb.

7. Cervical six, seven and eight and thoracic one

One dog was used for this neurectomy. The limb dangled lifelessly with the elbow slightly flexed and the carpus flexed. No attempt was made to advance the limb. The dorsal surface of the carpus and digits was lightly drawn along the surface of the ground. Fig. 30A-F illustrate the typical positions exhibited by the injured limb.

F. Sequellae Exhibited Six Months After Nerve Resection

The loss of the trophic influence of a muscle nerve supply causes the muscle to atrophy very quickly. The atrophy can be noted as early as ten days and reaches a maximum after three months.

When the motor nerve supply is lost by a muscle, flaccid paralysis

Fig. 29. Effects of neurectomies performed on the seventh, and eighth cervical and the first thoracic spinal nerves.

Note how the animal always places the dorsal surface of the carpus and digits on the surface of the ground. This resembles a typical pose for severe clinical cases of brachial plexus damage. Note that even when the animal stands very straight, picture A and C, that the leg appears to be several inches too long, because of considerable dropping of the elbow.



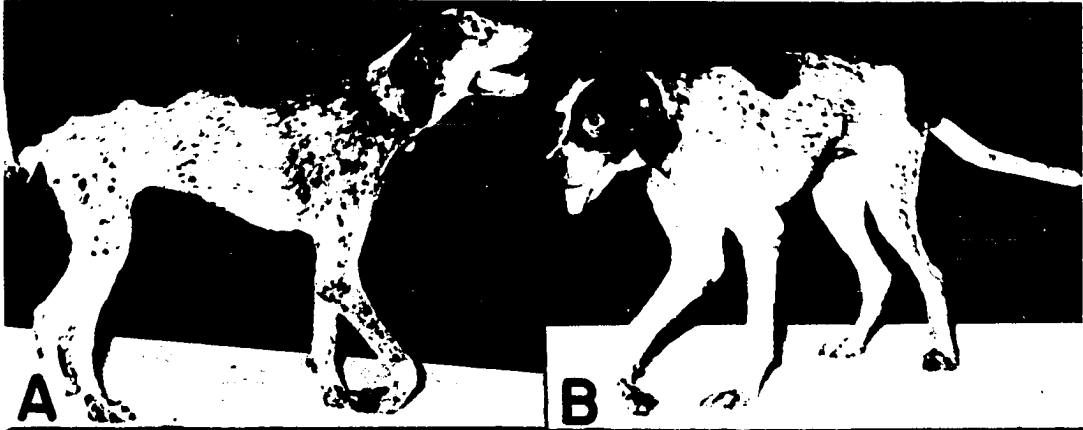
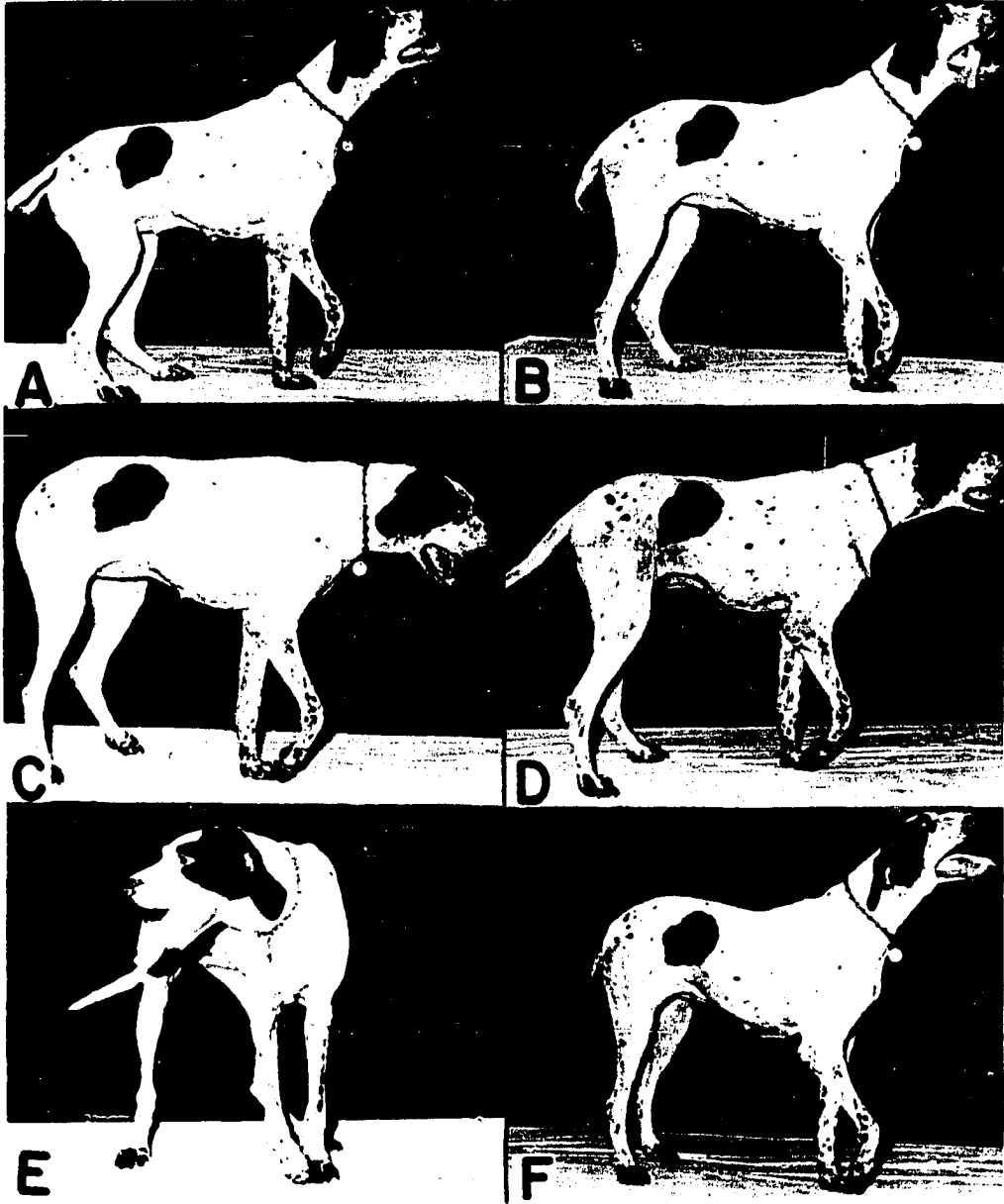


Fig. 30. Effects of neurectomies performed on the sixth, seventh, and eighth cervical and the first thoracic spinal nerves.

Note how the limb hangs in a lifeless position. The volar surface of the paw is never placed on the surface of the ground.



occurs. There is natural tonus in muscles even when at rest, and only very deep anesthesia will ever abolish the muscle tonus. However, in flaccid paralysis of a muscle, the tonus is absent in the affected muscles. Muscles work in antagonistic groups. While one group of muscles are contracting, causing a flexion of a joint, another group are relaxing and stretching, getting ready to perform the opposite action of extension. When only one group of these muscles are denervated, for example, the triceps brachii, the antagonists to the triceps brachii muscles, the biceps brachii and brachialis muscles, cause a constant contraction. Since there is no resistance to the flexion of the elbow and extension does not take place, the tendons soon undergo permanent shortening which is known as "contracted tendon". Fig. 31A-F illustrate the various types of contracted tendons due to loss of specific innervation.

Fig. 31C illustrates the atrophy of the extensors of the carpus and digits. There is only a slight dorsal buckling of the carpus due to contraction of the flexor tendons. Fig. 31D and F illustrate extreme contraction of the flexor tendons of the elbow and carpal joints.

Fig. 32A illustrates the carriage of the affected limb when the superior radial nerve alone is resected. Note the flexion of the elbow in picture A. At rest, Fig. 32B, the same dog cannot rest the paw on the ground due to contraction of the tendons. Note, however,

Fig. 31. Sequellae of various neurectomies six months post operatively.

A-B. Effects of resection of the superior radial nerve trunk

C. Effects of resection of the inferior radial nerve trunk

D. Superior radial neurectomy, illustrating that the flexor tendons of the elbow and carpus are permanently contracted

E-F. Radial, musculocutaneous, median-ulnar and axillary

Note the contraction of the flexor tendons and atrophy of extensor muscles. Note picture F demonstrates that the tendons cannot be straightened. Also note the ulcers on the toes and dorsal surface of the carpus.

G. Radial and thoracodorsal nerves

The elbow and shoulder joints are carried in the flexed position.

H-I. Radial, musculocutaneous and thoracodorsal nerves

There is not as much tendon contraction when both flexors and extensors are denervated.

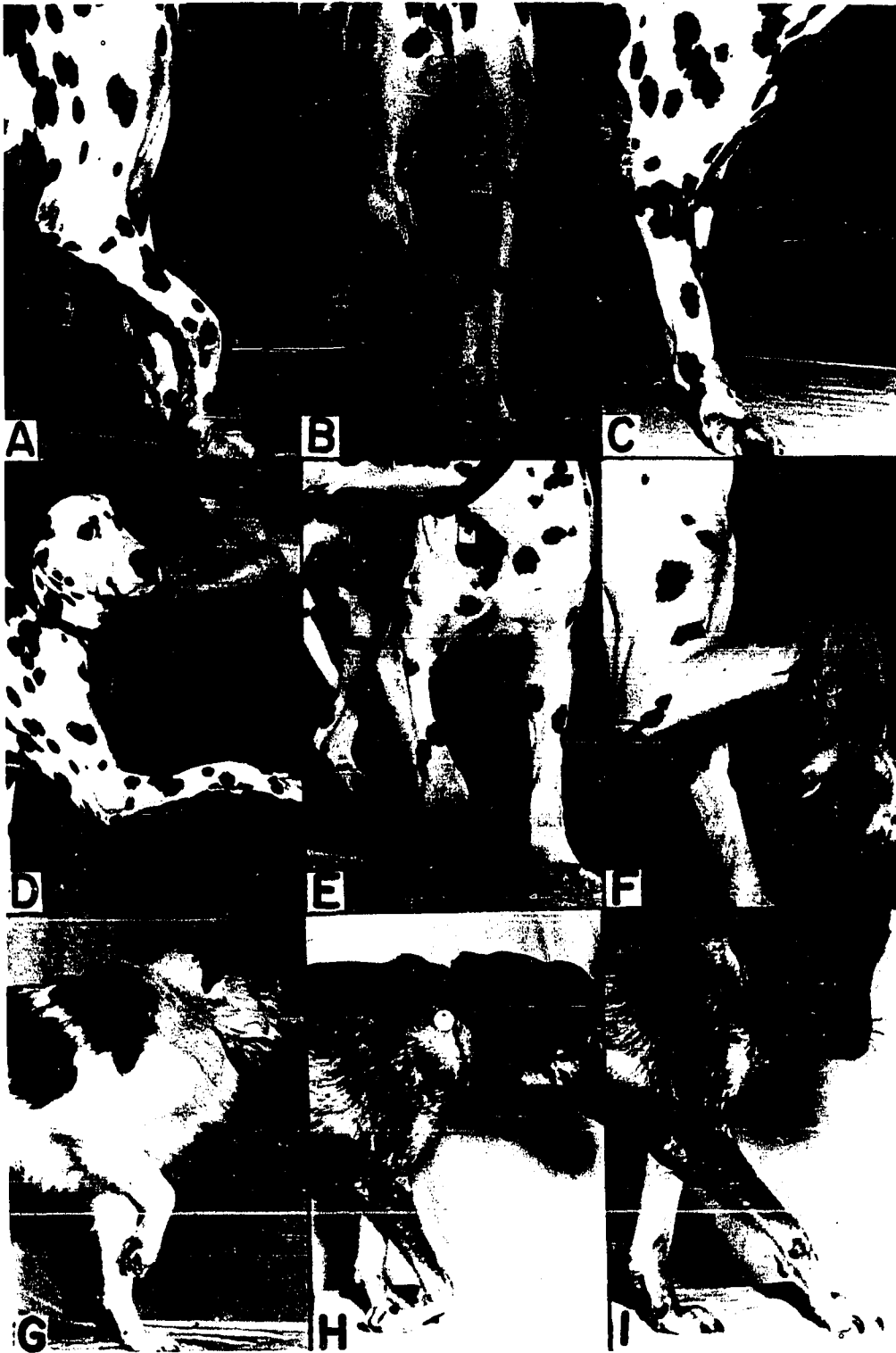

Fig. 32. Sequellae of various nerve resections six months post operatively.

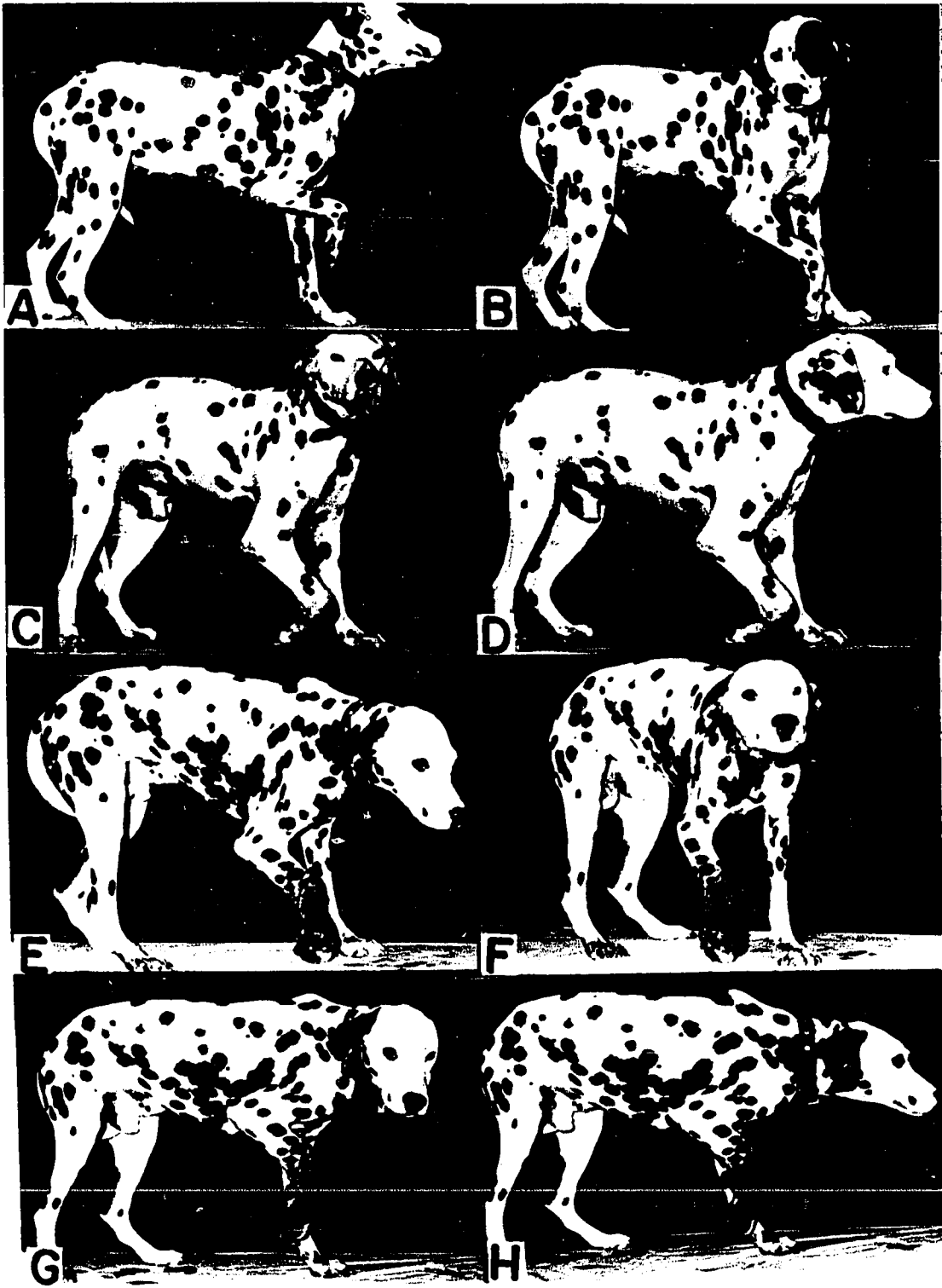
A-B. Superior radial neurectomy

Note the typical carriage in picture A.
Note further that the volar surface of the paw, picture B, cannot be extended to the surface of the ground.

C-D. Radial, musculocutaneous, median-ulnar and axillary nerves

E-H. Radial, musculocutaneous and median-ulnar nerves

Note the attempt at self amputation due to the absence of sensory innervation.



in Fig. 32C and D that the tendon contraction is not as extensive in the flexors of the elbow as they are also flaccid, therefore, the arm cannot be held off the surface of the ground and the carpus knuckles over on the dorsal surface and the tendons contracted in that position. They cannot be straightened out even under severe manual manipulation. Fig. 31F.

Fig. 33A-F compares favorably with poses seen in clinical cases of brachial plexus paralysis, some months after an accident.

Fig. 34C-H shows the typical position that the leg was held six months after the sixth, seventh and eighth cervical nerves were sectioned. Note that the limb cannot be extended. Ten days after resection the affected limb could be partially advanced and weight could be supported on the limb. Six months later the extensors of the elbow, carpal and digital joints are contracted as far as the joints will allow. The shoulder was flexed because the long head of the triceps brachii muscle extends from the olecranon process of the ulna to the caudal angle of the scapula. It contracted because there were no antagonists to counteract its action. The animal can no longer advance the limb enough to rest the volar surface of the paw on the surface of the ground.

Another sequellae of loss of innervation is the loss of sensation. The animal drags the dorsal surface of its carpus on the ground and it becomes abraded and sore. It may lay on its affected limb until dicubitus ulcers develop, Fig. 35A-C. The damage to the soft tissues

Fig. 33. Sequellae to resection of the radial, musculo-
cutaneous and thoracodorsal nerves.

Note progressive contraction of tendons.
Picture C is as near as the animal is capable
of placing the volar surface of the paw on the
surface of the ground.



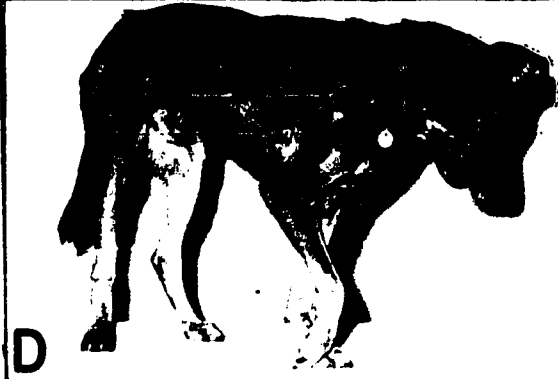


Fig. 34. Sequellae of neurectomies performed on nerves of the brachial plexus.

A-B. Radial and thoracodorsal

C-H. Cervical six, seven and eight spinal nerves

Note in pictures A and B that the tendons have contracted so that the foreleg can no longer contact the surface of the ground.

Note in pictures C-H that the leg is stiff and cannot be advanced. The leg cannot be advanced enough to bear weight. At ten days the leg could be advanced and the leg was supporting weight.



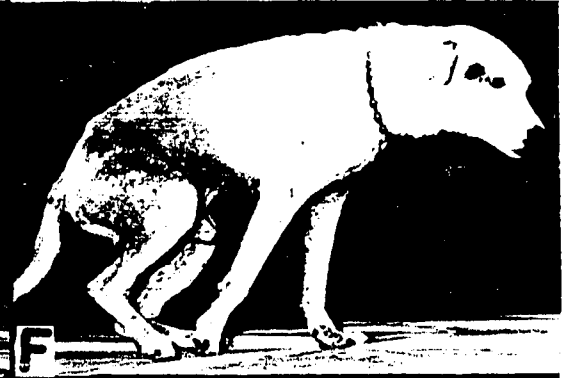





Fig. 35. Effects of loss of innervation of the muscles of the forelimb.

A-C. Cervical six, seven, eight and thoracic one spinal nerves

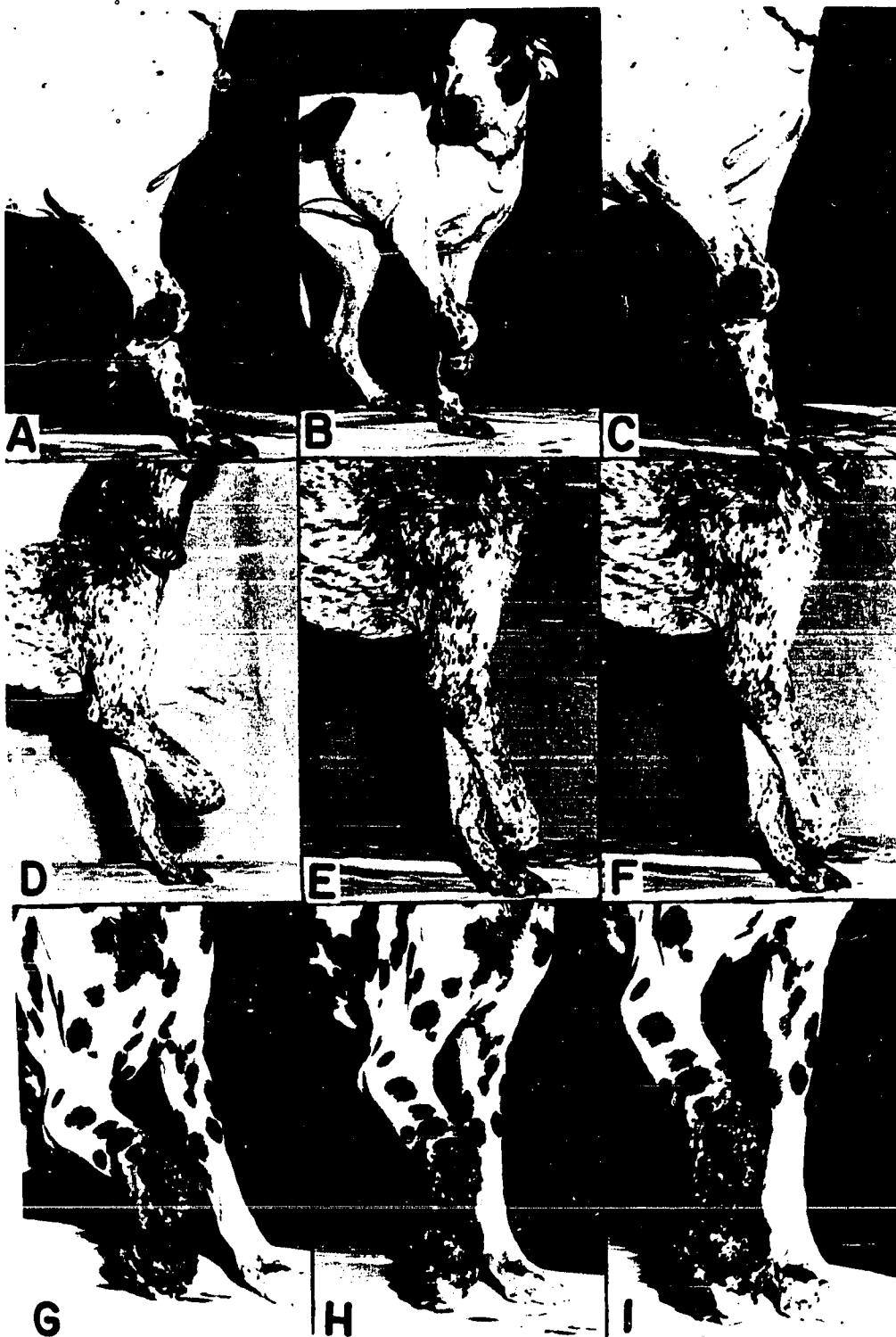Note the dicubitus ulcer that would have eventually been removed by the animal.

D-F. Cervical seven, eight and thoracic one spinal nerves

Note that the leg below the carpus has been self amputated. This was done in one evening.

G-I. Radial, musculocutaneous and median-ulnar nerves

Note the ulceration and granulation tissue. This started as a small ulcer and progressed overnight to this condition due to the attempts of the animal to self amputate. This necessitated emergency surgical amputation. The resulting wound was very difficult to heal due to loss of innervation.



increase with repeated trauma. The healing processes are retarded because of the loss of the trophic influence of the nerves. When the wound becomes necrotic or the limb gets in the way, the animal will proceed to amputate the limb. Fig. 32E-H and Fig. 35G-I illustrate a severe example of self mutilation due to necrosis and loss of sensation. This lesion was an ulcer similar to that seen in Fig. 31F and Fig. 35A-C. It was being treated palliatively one day and the next day the dog had removed the leg almost off at the carpus. It was not infected nor did it have an objectionable odor, but once started the leg will be quickly amputated by the dog. Fig. 35D-F and Fig. 36F illustrate an animal that completely amputated its leg below the carpus in less than twelve hours.

Denervation will cause atrophy of the muscle, loss of sensation, contraction of tendons and eventually self mutilation.

F. Motor Nerve Fibers in the Various Nerves of the Brachial Plexus

1. General considerations

The findings reported in this phase of the investigation are only a portion of another problem. No attempt will be made in this investigation to quantitate the findings. Special techniques have yet to be worked out to definitely classify the types of myelinated nerve fibers to be found in the nerves of the brachial plexus. When the ventral root is cut the



Fig. 36. Sequellae of denervation of the forelimb six months post operatively.

A-E. Radial, musculocutaneous and thoraco-dorsal

These poses closely resemble clinical patients observed some time after a car accident.

F. Cervical seven, eight and thoracic one spinal nerves

Lateral view illustrating self amputation of the leg below the carpus. There is no innervation below the elbow and it is conceivable that if the animal hadn't been destroyed it may have amputated the leg proximally to the elbow.



fibers supplied by that portion of the spinal nerve degenerate, and this degeneration can be followed by histological methods.

The slides of the various nerves were studied and were included in this investigation because they either reinforced the information established by gross dissections or supplied additional valuable information.

The degenerating motor fibers were counted in the spinal nerves before they branched. The degenerating nerve fibers were also counted in all the nerves supplied by the various spinal nerves and it was found that there are more degenerating fibers in the various nerves of the brachial plexus than in the spinal nerves that supply them. This evidence indicates that the motor fibers must branch profusely.

2. Cervical six

The brachiocephalicus as well as the suprascapular and subscapular nerves receive motor fibers from the ventral root of the sixth cervical spinal nerve. The musculocutaneous nerve received motor fibers in two instances and in the other, no fibers were found to come from the sixth cervical spinal nerve. This is in accord with the gross dissection findings. The axillary nerve received motor fibers in two instances and not in another. The axillary nerve was not found to be connected with the sixth cervical by gross anatomical dissections. The superficial pectoral received motor fibers from the sixth cervical in two cases and

not in the other case. In one case out of three the coracobrachialis nerve received motor fibers from the sixth cervical spinal nerve. Degeneration studies indicated that the sixth cervical spinal nerve supplied motor fibers to the superior radial trunk in two of three cases and to the inferior radial trunk in all three cases observed. The sixth cervical spinal nerve was not observed contributing to the radial nerve in any of the gross dissections. Fig. 37A and B. and Fig. 38G and H illustrate the distribution of the degenerating motor fibers in some of the nerves supplied by the sixth cervical spinal nerve.

3. Cervical seven

Only two individuals were used in the evaluation of the seventh cervical ventral spinal nerve root, because examination of the seventh cervical nerve in one individual revealed no degenerating nerve fibers, and the condition of the rest of the nerves indicated that cervical eight probably was resected instead of seven. The suprascapular, subscapular, musculocutaneous, axillary, superior and inferior radial, thoracodorsal, superficial pectoral and median, below anastomosis from the musculocutaneous, were supplied with motor fibers from the seventh cervical ventral spinal root. The two cases revealed many degenerating fibers in the seventh cervical spinal nerve.

The anastomosis between the musculocutaneous and median nerves revealed degenerating nerve fibers. This was borne out by the response

Fig. 37. Degeneration resulting from resection of the ventral roots of the spinal nerves that form the various nerves of the brachial plexus.

- A. Cervical six ventral root, the musculocutaneous nerve, 105X
- B. Cervical six ventral root, the brachiocephalicus nerve, 180X
- C. Cervical eight ventral root, the thoracodorsal nerve, 180X
- D. Cervical eight ventral root, the coracobrachialis nerve, 600X
- E. Cervical eight ventral root, the deep pectoral nerve, 350X
- F. Cervical eight ventral root, the lateral thoracic nerve, 250X
- G. Thoracic one ventral root, the deep pectoral nerve, 180X
- H. Thoracic one ventral root, the axillary nerve, 105X

The degenerating motor nerve fibers are represented by the black dots or black doughnut-like rings. The myelin rings are well represented in picture D.

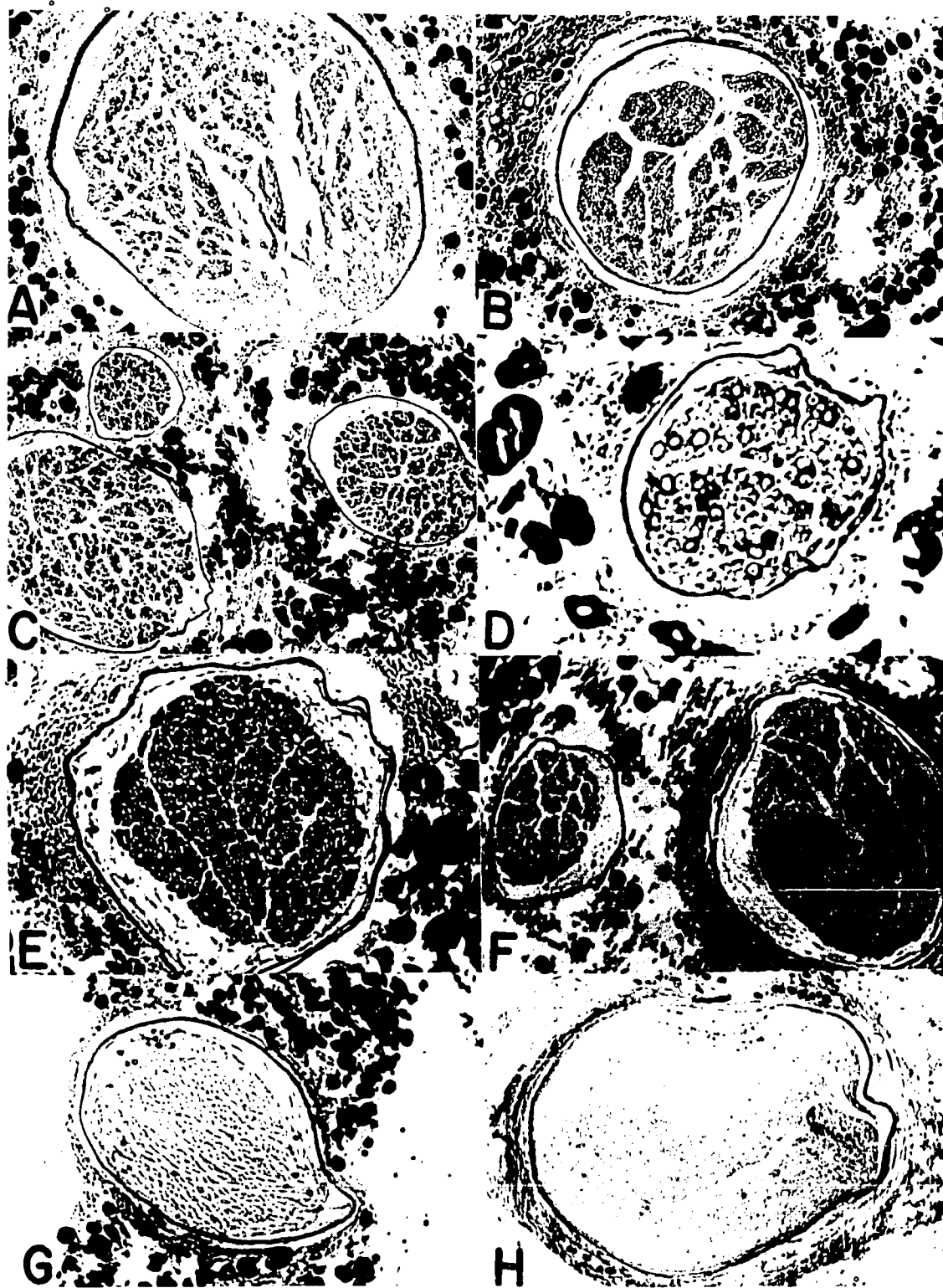

Fig. 38. Degeneration resulting from resection of the ventral roots of the spinal nerves that form the various nerves of the brachial plexus.

A-C. Cervical seven ventral roots, inferior radial nerve trunk, 250X. Note the number of degenerating motor fibers. A, B and C each represent a different funiculus as seen in picture H.

D. Cervical seven ventral root, anastomosis between the median and musculocutaneous nerves, 450X. This finding supports the results of the faradic stimulation of the musculocutaneous nerve, and the motor response in the flexors of the carpus and digits.

E. Cervical seven ventral root, the thoracodorsal nerve, 240X

F. Cervical seven ventral root, the spinal nerve trunk of the seventh cervical, 87.5X

G. Cervical six ventral root, the suprascapular nerve, 105X

H. Cervical six ventral root, the inferior radial nerve trunk, 105X



to faradic stimulation and was suspected when the median-ulnar neurectomies did not cause atrophy of the flexors of the carpus and digits.

Fig. 38A-C illustrate a relative high power photomicrograph of the degenerating motor fibers in the inferior radial nerve trunk. The black doughnut-like rings of myelin are the structures studied. Fig. 38D illustrates the distribution of motor fibers in the anastomotic branch between the musculocutaneous and median nerves. Fig. 38E and F illustrate the thoracodorsal and seventh spinal nerves respectively.

4. Cervical eight

All three experimental animals revealed degenerating motor nerves in their respective eighth cervical spinal nerves. The axillary received motor fibers in two of the three individuals. The superior radial, inferior radial, thoracodorsal, median-ulnar, median, ulnar, lateral thoracic, deep pectoral, coracobrachialis and musculocutaneous nerves received motor fibers from the ventral root of the eighth cervical spinal nerve. It was interesting to note that in all three individuals the coracobrachialis nerve was supplied by the eighth cervical nerve. This of course does not rule out the seventh as also supplying the coracobrachialis nerve of these animals with motor fibers. Fig. 37C-F illustrates some of the nerve supplied by the eighth cervical spinal nerve.

5. Thoracic one

Three individuals were used in these tabulations. The third individual revealed fewer numbers of degenerating fibers in the first thoracic spinal nerve when compared to the other two experimental animals.

The superior and inferior radial, median-ulnar trunk, median, ulnar and lateral thoracic nerves contained degenerating fibers. This indicated that they were receiving motor fibers from the first thoracic spinal nerves. Gross dissection procedures revealed that the second thoracic did not contribute to the brachial plexuses of these animals. The axillary nerve was supplied with motor fibers in one out of the three cases. The deep pectoral and thoracodorsal nerves were supplied by the first thoracic spinal nerve in one individual. Fig. 37G and H illustrate the deep pectoral and axillary nerves being supplied with motor fibers from the first thoracic spinal nerve.

V. DISCUSSION

A. Macroscopic Anatomy of the Brachial Plexus

The brachial plexus of nerves in the dog originated from the fifth cervical through the second thoracic spinal nerves. Miller (1952) and Bradley and Grahame (1948) state that it arises from the sixth, seventh, eighth cervicals and the first and second thoracic. Sisson and Grossman (1953) state that it arises from cervical five through thoracic one spinal nerves. Allam et al. (1952) state that the largest percentage of the plexuses (58.62%) originate from cervical six through thoracic one spinal nerves. In this investigation, 34.62 percent originated from cervical six through thoracic one spinal nerves, and 55.77 percent arose from cervical six through thoracic two. Careful dissection of the distribution of the second thoracic spinal nerve revealed that it often passed directly through the stellate ganglion and joined the first thoracic spinal nerve trunk. This type of radical dissection may be in error, but the fibers appeared to pass through the stellate ganglion when checked under a dissection binocular microscope at sixty magnifications. This problem can be further resolved with electro-physiological methods or by experimental nerve degeneration techniques.

The brachiocephalic nerve originated from the ventral branch of the sixth cervical spinal nerve. This is in agreement with Miller (1952)

and Bradley and Grahame (1948). When the fifth cervical spinal nerve contributed to the plexus it joined the brachiocephalicus, which bears out a similar statement by Allam et al. (1952).

The musculocutaneous nerve is an important nerve in the plexus as it is the sole supply to the flexors of the elbow. Miller (1952) and Allam et al. (1952) state that the musculocutaneous nerve originates from cervical seven and has no connections with the eighth cervical spinal nerve. The nerve was observed to originate from the seventh and eighth cervicals as well as the seventh cervical spinal nerve alone in this investigation. There were also degenerating motor nerve fibers in the musculocutaneous nerve when the ventral root of the eighth cervical nerve was resected.

The superficial pectoral nerve originated about equally from the musculocutaneous (45.24%) and the combined seventh and eighth cervical spinal nerve (35.72%). This is in agreement with Miller (1952).

The axillary nerve originated about equally from the seventh cervical alone and the combined seventh and eighth cervical spinal nerves. Although no percentages are quoted by them, the findings are in general agreement with Miller (1952) and Ellenberger and Baum (1943). Bradley and Grahame (1948) and Allam et al. (1952) state that the axillary is derived exclusively from the seventh cervical spinal nerve. Degenerating fibers were found in the axillary nerve trunk when

the ventral root of the eighth cervical spinal nerve was resected.

Fig. 37H illustrates the degenerating motor fibers seen in the axillary nerve when the first thoracic spinal nerve was resected.

This investigation is in agreement with the authors reviewed on the origin of the radial and median-ulnar nerves. However, degeneration studies indicated that the sixth cervical spinal nerve may contribute motor fibers to the radial nerve trunks. This observation could not be confirmed by gross dissection procedures. Fig. 38H illustrates the inferior radial nerve trunk after resection of the sixth cervical spinal nerve.

Allam et al. (1952) state that the coracobrachialis nerve originates from the radial nerve. This could not be substantiated by this investigation. The coracobrachialis nerve originated from the musculocutaneous nerve (54.17%) and from the musculocutaneous and eighth cervical in 35.42 percent of the dissections. The coracobrachialis nerve was observed to contain degenerating motor fibers when the ventral root of the eighth cervical spinal nerve was resected (Fig. 37D). In one out of three animals the coracobrachialis nerve was observed to contain degenerating motor fibers when the sixth cervical ventral spinal root was resected. This latter fact could not be substantiated by gross dissections.

This investigation established that the musculocutaneous contribute motor fibers to the flexors of the carpus and digits by way of the

anastomotic branch between the musculocutaneous and median nerves. This was proved by faradic stimulation, and also degenerating fibers were found in the anastomotic branch (Fig. 38D) when the seventh cervical motor root was resected.

Degenerating motor nerve fibers were observed in the superior and inferior radial nerve trunks when the ventral root of the sixth cervical spinal nerve was resected. This indicates that gross dissection procedures are inadequate in establishing accurate origins of the various nerves of the brachial plexus of the dog.

Faradic stimulation of the various nerves of the brachial plexus established many distinguishing static attitudes that helped in the evaluation of the effects of various neurectomies on the nerves of the brachial plexus. The brachiocephalic nerve innervates a portion of the brachiocephalicus muscle. Stimulation of the brachiocephalic nerve caused the limb to be lifted from the ground and advanced. Stimulation of the suprascapular nerve caused extension of the shoulder joint. Stimulation of the musculocutaneous nerve caused flexion of the elbow and carpal joints. The flexion of the carpus, as stated previously, is due to the connection of the musculocutaneous nerve with the median nerve.

Faradic stimulation of the axillary nerve caused flexion of the shoulder and adduction of the elbow joint. This typical attitude was seen when the musculocutaneous and superior radial nerves were resected.

The superior radial nerve trunk, when stimulated, elicited the following actions: the elbow and carpal joints were extended and the digital joints were over extended and splayed. Stimulation of the inferior radial nerve was puzzling at first, since it caused flexion of the elbow joint. Flexion is not observed when the triceps are also stimulated. However, the inferior radial nerve was shown to be capable of flexing the elbow joint. The latter observation helped explain the flexion of the elbow joint when the musculocutaneous nerve was resected.

Stimulation of the lateral thoracic nerve was observed to cause contraction of the preputial muscle, an observation not recorded in the literature on the dog up to the time of this investigation. Stimulation of the coracobrachialis nerve caused the muscle of like name to weakly flex the shoulder joint. Miller (1952) states that the coracobrachialis muscle is an extensor of the shoulder.

B. Effects of Resection of the Various Nerves of the Brachial Plexus

Slow motion moving pictures of the gaits of the experimental animals showing the effects of the various neurectomies facilitated an accurate description. The symptoms manifested by clinical cases of brachial plexus damage are varied. An attempt is made in this investigation to reproduce on experimental animals the various syndromes observed in

clinical cases of brachial plexus damage.

The musculocutaneous, axillary, median-ulnar nerves, when sectioned on different animals, caused no noticeable symptoms in the experimental animals. This substantiates the observations made by Worthman (1958). However, resection of the radial nerve as it courses around the musculospiral groove did not cause any noticeable symptoms after the effects of surgical trauma had disappeared. This would seem to invalidate Kirk's (1951) statement that "radial paralysis, dropped elbow, is due to blows in the region of the elbow." Robinette (1955) states that the most prominent symptom of radial paralysis is the inability of the animal to carry the affected limb forward. In this investigation the affected limb could be advanced under almost any combination of neurectomies except cervicals six, seven and eight, or when the brachiocephalic, suprascapular and radial nerves were resected on the same individual. Brumley (1943) describes radial paralysis as a limp, lifeless condition of the limb. This condition was approximated in this investigation only when the sixth, seventh and eighth cervicals and first thoracic spinal nerves were resected. Even in these experimental animals the dorsal aspect of the foot was not always in contact with the surface of the ground. Hutyra et al. (1938) state that the animal can advance the affected limb, but they further state that the elbow joint can, under certain condition bear weight. In this investigation the elbow joint could not bear any weight.

if the superior radial nerve was resected. However, if the sixth, seventh and eighth cervical spinal nerves are resected, the animal is definitely lame, but it can support weight on the affected limb.

The symptoms that the various investigators reviewed describe were never reproduced by resection of the superior radial nerve alone. The symptoms that the investigators described were closely approximated when the superior radial, which controls the extensor of the elbow, carpus and digits; the musculocutaneous nerve, which along with the inferior radial controls flexion of the elbow, and the axillary and thoracodorsal nerves, which control flexion of the shoulder joint, are resected in the same individual. The elbow drops, because the extensor muscles of the elbow joint are not functioning. The dorsal surface of the digits and carpus rest on the ground because the flexors of the elbow and shoulder joints cannot take up the slack caused by the relaxation of the triceps brachii muscles. If this description does describe a typical sequellae to brachial plexus damage, it cannot under any circumstances be representative of all syndromes that may be seen in clinical patients. There are approximately eight different combinations of experimental nerve damage that will cause severe, but specific symptoms. Resection of the superior radial nerve alone will cause the elbow to be carried in the flexed position, or resection of the radial and musculocutaneous nerves in the same individual will cause the shoulder

to be flexed and the foreleg to hang loosely, perpendicular to the surface of the ground. Resection of the superior radial, musculocutaneous and axillary nerves in the same individual will cause the limb to be dropped, but the latissimus dorsi, innervated by the thoracodorsal nerve, will cause the limb to be drawn posteriorly and cause flexion of the shoulder joint. If the superior radial, musculocutaneous, axillary and thoracodorsal nerves are resected on the same individual the limb drops into the often described clinical picture of "radial paralysis". However, the limb can still be advanced due to the action of the brachiocephalicus and supraspinatus and infraspinatus muscles.

In some clinical cases observed during the course of this investigation, the various spinal nerves that contribute to the brachial plexus were found upon postmortem examination to be avulsed from the spinal cord. Experimental animals in which the various spinal nerves were resected indicated that the classic description of "radial paralysis" can be reproduced by resection of certain combinations of spinal nerves. Resection of the sixth, seventh, and eighth cervical and the first thoracic spinal nerves reproduced the lifeless condition of the limb as described by Brumley (1943). If the sixth, seventh and eighth cervical spinal nerves were resected the animal was able to bear weight, and a condition similar to the one described by Hutyra et al. (1938) was reproduced.

A description of the sequellae to resection of the sixth, seventh and eighth cervical spinal nerves was not found in the literature reviewed to date. It may be that the condition is so severe that euthanasia or amputation was performed before the symptoms, which take about six months to reach a maximum, could be observed. Resection of the seventh and eighth cervical and first thoracic spinal nerves caused symptoms typical of textbook descriptions of "radial paralysis". The elbow was dropped, the carpus flexed and the dorsal surface of the carpus and digits rest upon the surface of the ground. However, the condition is not lifeless as the experimental animal was able to advance the affected limb because the sixth cervical spinal nerve was still furnishing motor innervation to the brachiocephalicus, supraspinatus and infraspinatus muscles.

If the neurectomies that are severe enough to cause symptoms are not treated immediately and continuously a very grave prognosis must be given for functional recovery of the affected limb. This investigation indicates that there are three sequellae that may become irreversible if not attended immediately. The tendons of the muscles that are antagonists to those that are denervated will contract. Only drastic surgical intervention can possibly alleviate the contraction if allowed to become advanced. The muscles that are denervated will atrophy. In this investigation it was found that atrophy began as early as ten days and reaches

a peak three months after the muscle is denervated. The muscle tissue just disappears due to the loss of the trophic influence of the nerve supply. These latter two conditions can happen to naturally occurring cases of brachial plexus damage. The third sequellae, self mutilation, is the final outcome of denervation if the affected limb becomes abraded and necrotic, and if the sensory innervation is also abolished.

VI. SUMMARY AND CONCLUSIONS

1. The brachial plexus of the dog originates from the ventral branches of the fifth, sixth, seventh and eighth cervicals and the first and second thoracic spinal nerves. However, 55.77 percent of the plexuses dissected originated from cervical six through the second thoracic spinal nerves and 34.62 percent originated from cervical six through the first thoracic spinal nerves. The size of the branches supplied to the plexus from the fifth cervical and second thoracic spinal nerves are very small when compared to the size of the rest of the contributors.

2. Gross dissection of cadavers, faradic simulation of living nerves and neuro-degeneration experiments were used to determine the origin of the various nerves of the brachial plexus.

3. The musculocutaneous nerve was found to contain degenerating fibers when the ventral root of the sixth, seventh and eighth cervical spinal nerves were resected on separate individuals. Gross dissection procedures found the eighth cervical spinal nerve origin in only 1.92 percent of the animals dissected.

4. The axillary nerve was found to originate from the seventh and eighth cervical spinal nerves in 50.98 percent and the seventh cervical spinal nerve alone in 42.06 percent of the animals dissected. Resection of the sixth, seventh and eighth cervical, and in one instance, the first

thoracic ventral roots of spinal nerves resulted in degenerating motor fibers to be observed in the axillary nerve. The origin from the first thoracic spinal nerve could not be substantiated by gross anatomical dissections.

5. The radial nerve originates from the axillary nerve, eighth cervical and the first thoracic spinal nerves in 55.77 percent of the animals dissected, and from the seventh, eighth cervical and first thoracic spinal nerves in 42.31 percent of the animals dissected. Degeneration studies indicate that there is a significant origin supplied to the radial nerve from the sixth cervical spinal nerve.

6. The median-ulnar nerve originates from the eighth cervical and first thoracic spinal nerves in 34.46 percent of the animals dissected, however, when the animal was observed to have a contribution from the second thoracic spinal nerve, the combination of cervical eight through thoracic two was described as being present in 59.62 percent of the animals dissected. It was found by faradic stimulation and degeneration studies that the anastomotic branch between the musculocutaneous and median nerves contained motor fibers. Therefore, the flexors of the carpus and digits can receive innervation from the sixth and seventh cervical spinal nerves via this connection.

7. Faradic stimulation of the various nerves of the brachial plexus categorized the function of each nerve of the plexus and helped in the

evaluation of the neurectomy experiments. It was found that when the lateral thoracic nerve was stimulated it caused the contraction of the preputial muscle.

8. Clinical cases of brachial plexus damage were studied and an attempt was made to duplicate the symptoms observed on experimental animals.

9. Resection of the superior radial trunk in an animal caused the affected limb to be carried so that the shoulder and elbow joints were flexed. The animal could not bear any weight on the affected limb.

10. Resection of the superior radial trunk, and musculocutaneous nerve caused the affected limb to be carried with the shoulder flexed, but the elbow hung loose and nearly perpendicular to the surface of the ground.

11. Resection of the superior radial, musculocutaneous, axillary and thoracodorsal nerves resulted in the shoulder joint being carried in the extended position, the elbow carried in a dropped position and the dorsal surface of the digits and carpus were knuckled over on the ground. The animal could still advance the affected limb.

12. Resection of the brachiocephalic, suprascapular, superior radial, musculocutaneous, axillary and thoracodorsal nerves caused a flaccid paralysis and dropping of the affected limb and it could not be advanced properly.

13. Resection of the sixth, seventh and eighth cervical spinal nerves caused the limb to be carried caudal to its normal position.

The animal could not advance the affected limb. However, the animal could bear weight on the affected limb until tendon contractions made it impossible for the volar surface of the paw to be placed on the surface of the ground.

14. The syndrome of "radial paralysis" should be called brachial plexus avulsion or involvement.

15. All of the possible combinations of neurectomies were performed that would cause observable symptoms. Brachial plexus paralysis can be manifested in many different manners. Each clinical case must be evaluated on closely observed symptoms and compared with known experimental neurectomies for an accurate diagnosis of foreleg paralysis.

16. The sequellae of brachial plexus damage include: loss of function of muscles that become denervated, atrophy of the muscles due to the loss of the trophic influence of the nerve, contraction of the tendons of the antagonist muscles because they have no resistance applied to them by the denervated muscles, and self mutilation and eventually self amputation.

VII. LITERATURE CITED

- Allam, M. W., Lee, Donald G., Nulsen, Frank E., and Fortune, E. A. 1952. The anatomy of the brachial plexus of the dog. *Anat. Rec.* 114:173-179.
- Barron, D. H. 1943. The early development of the motor cells and columns in the spinal cord of the sheep. *Jour. Comp. Neur.* 78: 1-27.
- _____. 1946. Observations on the early differentiation of the motor neuroblasts in the spinal cord of the chick. *Jour. Comp. Neur.* 85:149-169.
- Bell, G. H., Davidson, J. N., and Scarborough, H. 1957. Textbook of physiology and biochemistry. 3rd ed. Baltimore, The Williams and Wilkins Co.
- Bowne, John G. 1958. A multipurpose wound retractor for small animal surgery. *Jour. Am. Vet. Med. Assoc.* 133:158-160.
- Bradley, O. Charnock and Grahame, Tom. 1948. Topographical anatomy of the dog. 5th ed. London, Oliver and Boyd.
- Brumley, O. V. 1943. A textbook of the diseases of the small domestic animals. 4th ed. Philadelphia, Lea and Febiger.
- Burt, A. S., comp. 1952. Bibliography of genetic neuropathology. Nat. Acad. Sci. Nat. Res. Council. Pub. 237 (Suppl.)
- Causey, G. and Palmer, Elizabeth. 1952. Early changes in degenerating mammalian nerves. *Proc. Roy. Soc. London. Ser. B*, 139:597-609.
- _____ and _____. 1953. The centrifugal spread of structural changes at the nodes in degenerating mammalian nerves. *Jour. Anat.* 87:185-191.
- Clifford, D. H., Kitchell, R. L., and Knauff, D. R. 1958. Brachial paralysis in the dog. *Am. Jour. Vet. Sci.* 39:49-52.

- Detwiler, S. R. 1934. An experimental study of spinal nerve segmentation in *Amblystoma* with reference to the pleurisegmental contribution to the brachial plexus. *Jour. Exp. Zool.* 67:395-441.
- _____. 1935. The development of spinal ganglia following transplantation of the spinal cord with or without somites. *Anat. Rec.* 61:441-445.
- Ellenberger, W. and Baum, H. 1943. *Handbuch der Vergleichenden Anatomie der Haustiere*. 18th ed. Berlin, Springer-Verlag.
- Garbutt, Raymond J. 1938. *Diseases and surgery of the dog*. New York, Orange Judd Co., Inc.
- Hamburger, V. and Keefe, E. L. 1944. The effects of peripheral factors on the proliferation and differentiation in the spinal cord of chick embryos. *Jour. Exp. Zool.* 96:223-242.
- Hines, M. 1927. Nerve and muscle. *Quart. Rev. Biol.* 2:149-180.
- Hobday, Frederick. 1953. *Hobday's surgical diseases of the dog and cat*. 6th ed. London, Bailliere Tindall and Cox.
- Howell, A. B. 1933. Morphogenesis of the shoulder architecture. Part IV. Therian mammalia. *Quart. Rev. Biol.* 12:440-463.
- Hutyra, Franz, Marek, Joseph, and Manninger, Rudolph. 1938. *Special pathology and therapeutics of the diseases of domestic animals*. 4th ed. Vol. 3. Chicago, Alexander Eger.
- Kerr, Abram T. 1918. The brachial plexus of nerves in man, the variations in its formation and branches. *Am. Jour. Anat.* 23:285-395.
- Kirk, Hamilton. 1951. *Index of treatment in small animal practice*. 2nd ed. Baltimore, The Williams and Wilkins Co.
- Lehmann, F. E. 1927. Further studies on the morphogenetic role of the somites in the development of the nervous system of amphibians. The differentiation and arrangement of the spinal ganglia on *Pleurodeles waltli*. *Jour. Exp. Zool.* 49:93-129.
- Logan, J. E., Rossiter, R. J. and Barr, M. L. 1953. Cellular proliferation in proximal segments of sectioned or crushed nerve. *Jour. Anat.* 87:419-422.

- Maximow, A. A. and Bloom, William. 1957. A textbook of histology. 7th ed. Philadelphia, W. B. Saunders.
- Miller, M. E. 1952. Guide to the dissection of the dog. 3rd ed. Ann Arbor, Michigan, Edwards Brothers, Inc.
- Miller, R. A. 1934. Comparative studies upon the morphology and distribution of the brachial plexus. *Am. Jour. Anat.* 54:143-175.
- _____ and Detwiler, S. R. 1936. Comparative studies upon the origin and development of the brachial plexus. *Anat. Rec.* 65: 273-292.
- Morris, Henry. 1953. Morris' human anatomy. 11th ed. New York, The Blakiston Co.
- Nageotte, J. 1932. Sheaths of the peripheral nerves: nerve degeneration and regeneration. In Penfield, W., ed. *Cytology and Cellular Pathology of the Nervous System*. Vol. 1, pp. 119-240. New York, Hoeber.
- Noback, C. R. and Reilly, J. A. 1956. Myelin sheath during degeneration and regeneration. II. Histochemistry. *Jour. Comp. Neur.* 105:333-353.
- Ramon y Cajal, Santiago. 1928. Degeneration and regeneration of the nervous system. Vol. 1 and 2. London, Oxford Univ. Press.
- Robinette, J. D. 1955. Canine radial paralysis. *West. Vet. (Pullman, Washington)* 2:42-48.
- Rosenblueth, A. and Del Pozo, E. C. 1943. The centrifugal course of Wallerian degeneration. *Am. Jour. Physiol.* 139:247-254.
- _____ and Dempsey, E. W. 1939. A study of Wallerian degeneration. *Am. Jour. Physiol.* 128:1-30.
- Sanders, F. K. and Young, J. Z. 1944. The role of the peripheral stump in the control of fiber diameter in regenerating nerves. *Jour. Physiol.* 103:119-136.
- Sisson, S. and Grossman, J. D. 1953. The anatomy of domestic animals. 4th ed. Philadelphia, W. B. Saunders Co.

Sunderland, Sydney. 1946. The effect of rupture of the perineurium on the contained nerve fibers. *Brain*. 69:149-152.

_____ and Bradley, K. C. 1950a. Denervation atrophy of the distal stump of a severed nerve. *Jour. Comp. Neur.* 3:401-409.

_____ and _____. 1950b. Endoneural tube shrinkage in the distal segment of a severed nerve. *Jour. Comp. Neur.* 93:411-420.

Swank, Roy Laver. 1940. Wallerian degeneration in the sciatic nerve of the rat. *Arch. Path.* 30:689-700.

_____ and Davenport, H. A. 1934a. Marchi's staining method: studies of some of the underlying mechanisms involved. *Stain Technology* 9:11-19.

_____ and _____. 1934b. Marchi's staining method: II. Fixation. *Stain Technology*. 9:129-135.

_____ and _____. 1935. Marchi's staining method: III. Artifacts and effects of perfusion. *Stain Technology*. 10:45-52.

Thorek, Philip. 1951. *Anatomy in surgery*. Philadelphia, J. B. Lippincott.

Weiss, P. 1941. Nerve patterns: the mechanics of nerve growth. *Growth*. 5:163-203. (supple.)

Wenger, B. S. 1951. Determination of structural patterns in the spinal cord of the chick embryo studied by transplantation between brachial and adjacent levels. *Jour. Exp. Zool.* 116:123-164.

Willier, B. H., Weiss, P. A., and Hamburger, V. 1955. *Analysis of development*. Philadelphia, W. B. Saunders Co.

Worthman, Robert P. 1957. Demonstration of specific nerve paralysis in the dog. *Jour. Am. Vet. Med. Assoc.* 131:174-178.

Yeary, R. A. 1956. Neurological diagnosis of foreleg paralysis in the dog. *Speculum (Ohio)*. 9:6, 40, 42.

Young, J. Z. 1942. The functional repair of nervous tissue. *Physiol. Rev.* 22:318-374.

Young, J. Z. 1945. Structure, degeneration and repair of nerve fibers. *Nature* (London). 156:132-136.

VIII. SELECTED BIBLIOGRAPHY

- Aitken, J. T. 1949. The effect of peripheral connection on the maturation of regenerating nerve fibers. *Jour. Anat.* 83:32-43.
- _____. 1950. Growth of nerve implants in voluntary muscle. *Jour. Anat.* 84:38-49.
- _____, Sharman, M., and Young, J. Z. 1947. Maturation of regenerating nerve fibers with various peripheral connections. *Jour. Anat.* 81:1-22.
- Allam, M. W. 1951. Diagnosis and prognosis of foreleg paralysis in the canine. *Vet. Excerpts.* 8:27-31.
- _____, Nulsen, F. E., and Lewey, F. H. 1949. Electrical intraneural bipolar stimulation of peripheral nerves in the dog. *Jour. Am. Vet. Med. Assoc.* 114:87-89.
- Baker, John R. 1946. *Cytological technique.* 2nd ed. London, Methuen and Co.
- Barron, D. H. 1945. The role of the sensory fibers in the differentiation of the spinal cord in sheep. *Jour. Exp. Zool.* 100:431-443.
- Bensley, Sylvia H. 1944. Cytological studies of the reaction of myelinated nerve fibers to section of the nerve. *Anat. Rec.* 90:1-15.
- Braus, H. 1909. Experimentelle Untersuchungen über die Segmentalstruktur der motorischen Nervenplexus. *Anat. Anz.* 34:527-551.
- Bucy, P. C. 1928. Studies in degeneration of peripheral nerves. *Jour. Comp. Neur.* 45:129-159.
- Bueker, E. D. 1943. Intracental and peripheral factors in the differentiation of motor neurones in transplanted lumbosacral cords of chick embryos. *Jour. Exp. Zool.* 93:99-129.
- Bullock, T. H., Cohen, M. J., and Faulstich, D. 1950. Effect of stretch on conduction in single nerve fibers. *Biol. Bull.* 36:59-81.
- Cannón, W. B. and Rosenblueth, A. 1949. *The supersensitivity of denervated structures.* New York, The Macmillan Co.

- Carey, Eben J. 1944. Early effects of inanition on the structure of motor end plates. *Anat. Rec.* 89:139-153.
- Chauveau, A., Arloing, S. and Fleming, George. 1902. The comparative anatomy of the domesticated animals. 2nd ed. New York, D. Appleton and Co.
- Cooper, S. and Sherrington, C. S. 1933. Degeneration of peripheral nerves after spinal transection in the monkey. *Jour. Physiol.* 77:18-19.
- Davenport, H. A. and Ranson, S. W. 1931. Ratios of cells to fibers and of myelinated to unmyelinated fibers in spinal nerve roots. *Am. Jour. Anat.* 49:193-208.
- Detwiler, S. R. 1920. Experiments on the transplantation of limbs in *Amblystoma*. The formation of nerve plexuses and the function of the limbs. *Jour. Exp. Zool.* 31:117-170.
- _____. 1927. The effects of extensive muscle loss upon the development of spinal ganglia in *Amblystoma*. *Jour. Exp. Zool.* 48:1-26.
- _____ and Lewis, R. W. 1925. Size changes in primary brachial motor neurons following limb excision in *Amblystoma* embryos. *Jour. Comp. Neur.* 39:291-300.
- _____ and Maclean, B. 1940. Substitution of limbs for brachial somites. *Jour. Exp. Zool.* 83:445-456.
- Duncan, D. 1932. A determination of the number of unmyelinated fibers in the ventral roots of the rat, cat, and rabbit. *Jour. Comp. Neur.* 55:459-471.
- Edds, M. V., Jr. 1949. Experiments on partially deneurotized nerves. I. Absence of branching of residual fibers. *Jour. Exp. Zool.* 111:211-226.
- _____. 1950. Hypertrophy of nerve fibers to functionally overloaded muscles. *Jour. Comp. Neur.* 93:259-275.
- _____. 1951. Atrophy of motor root fibers following destruction of sensory roots in the rat. *Anat. Rec.* 109:369-370.

- Edds, M. V., Jr. 1953. Collateral nerve regeneration. *Quart. Rev. Biol.* 28:260-276.
- Elliott, H. C. 1942. Studies on the motor cells of the spinal cord. *Am. Jour. Anat.* 70:95-117.
- Elsberg, C. A. 1917. Experiments on motor nerve regeneration and the direct neurotization of paralyzed muscles by their own and by foreign nerves. *Science.* 45:318-320.
- Esmond, U. G. and Smith, A. 1958. The structure of adult peripheral myelinated nerve fibers as revealed by phase microscopy. *Exp. Cell. Res.* 14:430-433.
- Essex, Hiram E. and de Rezende, Nelson. 1943. Observations on injury and repairs of peripheral nerves. *Am. Jour. Physiol.* 140:107-114.
- Fatt, P. and Katz, B. 1952. Spontaneous subthreshold activity at motor nerve endings. *Jour. Physiol.* 117:109-128.
- Feindel, W. H. 1954. Anatomical overlap of motor units. *Jour. Comp. Neur.* 10:1-17.
- _____, Hinshae, J. R., and Weddel, G. 1952. The pattern of motor annexation in mammalian striated muscle. *Jour. Anat.* 86:35-48.
- Feiss, H. O. 1912. On the fusion of nerves. *Quart. Jour. Exp. Physiol.* 5:1-30.
- Fernandez-Moran, H. 1952. The submicroscopic organization of vertebrate neurofibers. *Exp. Cell. Res.* 3:282-359.
- French, J. D. and Strain, W. H. 1947. Experimental contrast radiography of peripheral nerves. *Jour. Neuropath. Exp. Surg.* 6: 401-407.
- _____, _____, and Jones, G. E. 1948. Mode of extension of the contrast substance injected into peripheral nerves. *Jour. Neuropath. Exp. Surg.* 7:47-58.
- Goodrich, E. S. 1910. On the segmental structure of the motor nerve plexus. *Anat. Anz.* 36:109-112.

- Guth, L. 1956. Regeneration in the mammalian peripheral nervous system. *Physiol. Rev.* 36:441-478.
- Gutmann, E. 1945. The reinnervation of muscle by sensory nerve fibers. *Jour. Anat.* 79:1-8.
- _____, Gutman, L., Medawar, P. B., and Young, J. Z. 1942. The rate of regeneration of nerve. *Jour. Exp. Biol.* 19:14-44.
- Hammond, W. S. and Hinsey, J. C. 1945. The diameters of nerve fibers in normal and regenerating nerves. *Jour. Comp. Neur.* 83:79-92.
- Hare, W. K. and Hinsey, J. C. 1940. Reactions of dorsal root ganglion cells to section of peripheral and central processes. *Jour. Comp. Neur.* 73:489-502.
- Hiscoe, H. B. 1947. Distribution of nodes and incisures in normal and regenerated nerve fibers. *Anat. Rec.* 99:447-476.
- Hoerlein, B. F. 1953. Various contrast media in canine myelography. *Jour. Am. vet. Med. Assoc.* 123:311-314.
- Hoffman, H. 1950. Local re-innervation in partially denervated muscle: A histophysiological study. *Australian Jour. Exp. Biol. and Med. Sci.* 28:383-397.
- _____. 1952. Acceleration and retardation of the process of axon sprouting in partially denervated muscles. *Australian Jour. Exp. Biol. and Med. Sci.* 30:541-566.
- _____. 1954. Effects of a fibrosis-inhibiting substance on the innervation of muscles by nerve implants. *Jour. Comp. Neur.* 100:441-459.
- Holmes, W. 1951. Repair of nerves by suture. *Jour. Hist. Med.* 6:62-63.
- _____ and Young, J. Z. 1942. Nerve regeneration after immediate and delayed suture. *Jour. Anat.* 77:63-96.
- Huber, G. C. 1900. Observations on the degeneration of motor and sensory nerve endings in voluntary muscle. *Am. Jour. Physiol.* 3:339-344.

Joseph, J. 1947. Absence of cell multiplication during degeneration of non-myelinated nerves. *Jour. Anat.* 81:135-139.

Kilvington, B. 1905. An investigation on the regeneration of nerves, with a view to the surgical treatment of certain paralysis. *Brit. Med. Jour.* 1:935-940.

Kuffler, S. W. 1943. Specific excitability of the end plate region in normal and denervated muscle. *Jour. Neurophysiol.* 6:99-110.

Langworthy, O. R. 1930. Histological changes in nerve cells following injury. *Bull. Johns Hopkins Hosp.* 47:11-21.

Lash, James W., Holtzer, Howard, and Swift, Hewson. 1957. Regeneration of mature skeletal muscle. *Anat. Rec.* 128:679-693.

Lassek, A. M. 1953. Inactivation of voluntary motor function following brachial rhizotomy. *Jour. Neuropath. Exp. Neur.* 12:83-87.

_____ and Moyer, E. K. 1953. An ontogenetic study of motor deficits following dorsal brachial rhizotomy. *Jour. Neurophysiol.* 16:217-251.

Lues, J. V. and Eyzaguiove, C. 1955. Fibrillation and hypersensitivity to Ach in denervated muscle: Effect of length of degenerating nerve fibers. *Jour. Neurophysiol.* 18:65-73.

Lurje, A. S. 1948. Use of nervus musculocutaneous for neurolyzation of nervus radialis in cases of very large defects of the latter. *Ann. Surg.* 128:110-115.

Lyons, W. R. and Woodhall, B. 1949. Atlas of peripheral nerve injuries. Philadelphia, W. B. Saunders Co.

McGrath, J. T. 1956. Neurological examination of the dog with clinicopathological observations. Philadelphia, Lea and Febiger.

Nulsen, Frank E. and Lewy, F. H. 1947. Intra-neural bipolar stimulation: A new aid in the assessment of nerve injuries. *Science.* 106:301-302.

Palay, S. L. and Palade, G. E. 1955. The fine structure of neurones. *Jour. Biophysic. and Biochem. Cytol.* 1:69-88.

- Perret, G. 1951. Experimental and clinical investigations of nerve injuries of upper extremities. *Jour. Am. Med. Assoc.* 146: 556-560.
- Poirier, Louis J., Ayotte, Robert A., and Gauthier, Claude. 1954. Modification of the Marchi technic. *Stain Technology.* 29:71-75.
- Ranson, S. W. 1912. Degeneration and regeneration of nerve fibers. *Jour. Comp. Neur.* 22:487-545.
- Robinson, P. K. 1951. Associated movements between limb and respiratory muscles as sequel to brachial plexus burt injury. *Bull. Johns Hopkins Hosp.* 89:21-29.
- Sanders, F. K. and Young, J. Z. 1946. The influence of peripheral connexion on the diameter of regenerating nerve fibers. *Jour. Exp. Biol.* 22:203-212.
- Schmitt, F. O. 1957. The fibrous protein of the nerve axon. *Jour. Cell. Comp. Physiol.* (Suppl. 1) 49:165-174.
- _____ and Bear, R. S. 1939. The ultrastructure of the nerve axon sheath. *Biol. Rev.* 14:27-50.
- _____ and Geren, B. B. 1950. The fibrous structure of the nerve axon in relation to the localization of "neurotubules". *Jour. Exp. Med.* 91:499-504.
- Scott, Sidney. 1906. A record of the decussation of the brachial plexus. *Jour. Anat. and Physiol.* 40:412-415.
- Setterfield, H. E. and Sutton, T. S. 1935. The use of polarized light in the study of myelin degeneration. I. The appearance and progress of degeneration after transection of the sciatic nerve of the white rat. *Anat. Rec.* 61:397-411.
- Shorey, M. L. 1909. The effect of the destruction of peripheral areas on the differentiation of the neuroblasts. *Jour. Exp. Zool.* 7:25-63.
- Showe, G. D. H. 1955. Of the number of branches formed by regenerating nerve fibers. *Brit. Jour. Surg.* 42:474-488.
- Simpson, S. A. and Young, J. Z. 1945. Regeneration of fiber diameter after cross-unions of visceral and somatic nerves. *Jour. Anat.* 79: 48-65.

- Siwe, Sture A. 1931. The cervical part of the ganglionated cord, with special reference to its connections with the spinal nerves and certain cerebral nerves. *Am. Jour. Anat.* 48:479-491.
- Thomas, F. B. 1951. Improved splint for radial (musculospiral) nerve paralysis. *Jour. Bone and Joint Surg. Ser. B*, 33:272-273.
- Tower, Sarah S. 1939. The reaction of muscle to denervation. *Physiol. Rev.* 19:1-48.
- _____, Howe, H., and Bodian, D. 1941. Fibrillation in skeletal muscle in relation to denervation and to inactivation without denervation. *Jour. Neurophysiol.* 4:398-401.
- Tufvesson, G. 1951. Anestesi av Plexus brachialis. *Nord. Vet. Med.* 3:183-193.
- Vizoso, A. D. 1950. The relationship between internodal length and growth in human nerves. *Jour. Anat.* 84:342-353.
- _____, and Young, J. Z. 1948. Internode length and fiber diameter in developing and regenerating nerves. *Jour. Anat.* 82:110-134.
- Walsh, J. F. 1877. The anatomy of the brachial plexus. *Am. Jour. Med. Sci. N. S.* 74:387-397.
- Webb, E. M. 1954. Peripheral nerve injuries: early surgical treatment. *California Med.* 80:151-153.
- Weiss, P. 1944. The technology of nerve regeneration: A review. Sutureless tubulation and related methods of nerve repair. *Jour. Neurosurg.* 1:400-450.
- Wetzel, A. 1950. Radiolislahmung. *Tierarztliche Umschau.* 5:444-446.
- White, J. C. and Hanelin, J. 1954. Myelographic sign of avulsion. *Jour. Bone Joint Surg.* 368:113-118. 1954.
- Woodhall, B. 1954. Peripheral nerve injury. *Surg. Clin. North Am.* 34:1147-1165.

IX. ACKNOWLEDGMENTS

The author wishes to express his appreciation to Dr. Robert Getty for guidance, encouragement and constructive criticism given throughout the problem. He further wishes to express his appreciation to Dr. Raymond Morter and Dr. Warren Bohnhoff who assisted him when they were undergraduate students. He further wishes to thank Dr. Robert Billiar for the excellent drawings seen in Fig. 5, 12 and 13.

The author wishes to thank Dr. B. W. Kingery and Dr. Hugh D. Simpson for their cooperation and encouragement in experimental surgery. He wishes to thank Dr. R. M. Melampy for his constructive criticism of the thesis before it was sent to the typist.

The author wishes to thank his patient and understanding wife for her sustaining attitude and encouragement given throughout the course of graduate study.

The author wishes to thank Dr. William Monlux and Dr. Howard Hamilton for their timely tips and encouragement. He further wishes to thank Mr. William Haensley for the help in statistically evaluating the data on the brachial plexus. He wants to acknowledge with appreciation the support of Gaines Dog Foods, General Foods Corporation, Kankakee, Illinois, for furnishing all of the dog food used in this experiment. He also wishes to thank the Fort Dodge Laboratories, Fort Dodge, Iowa, for the biologicals used in the experiments.

The author knows the true value of other friends and wishes to express his gratitude for their counsel and support: Dr. J. Thomas Bell, Jr., Dr. George C. Christensen, Dr. James Jermier, Dr. Durwood Baker, Dr. Elroy Jensen and Dr. Margaret Sloss. He further wishes to thank Mrs. Nancy Huston for the technical assistance in preparation of the histological slides.

The author wishes to thank the Veterinary Medical Research Institute for the financial aid which supported in part this research project.